

Modern Treatment of Chest Wall Deformities

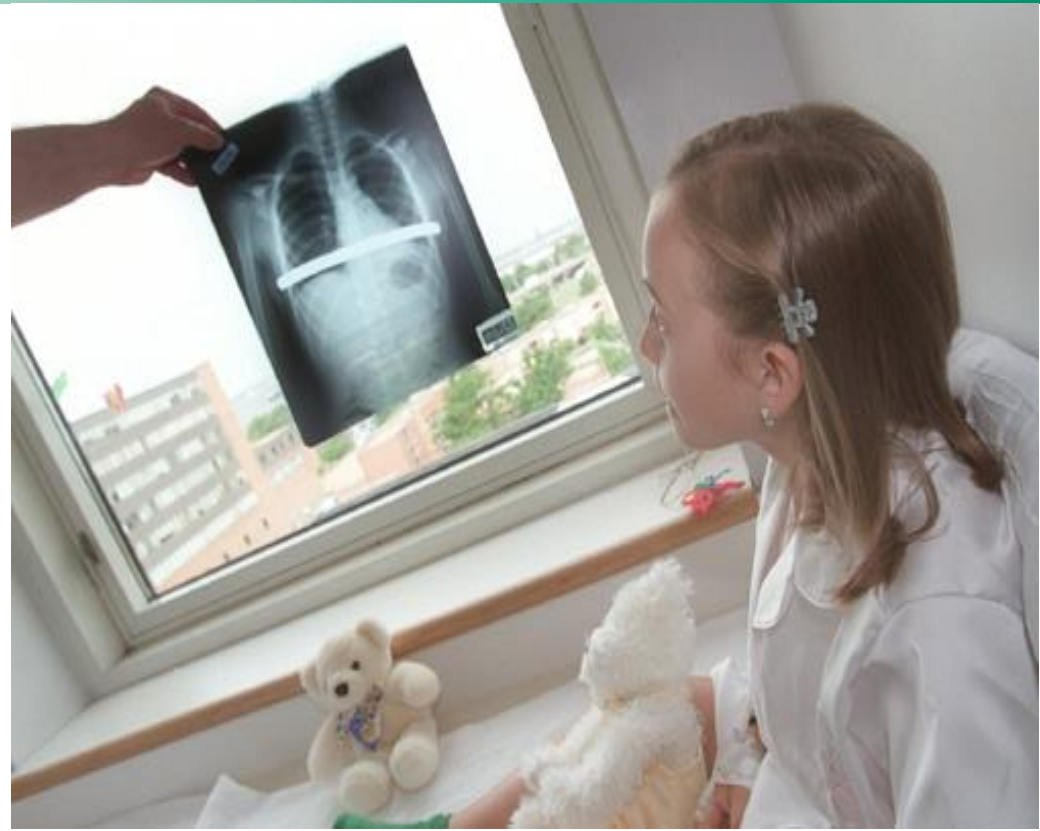 **INSELSPITAL**

UNIVERSITÄTSSPITAL BERN
HOPITAL UNIVERSITAIRE DE BERNE
BERN UNIVERSITY HOSPITAL

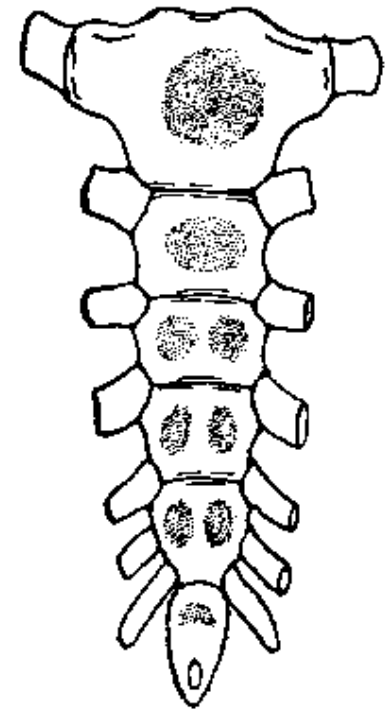
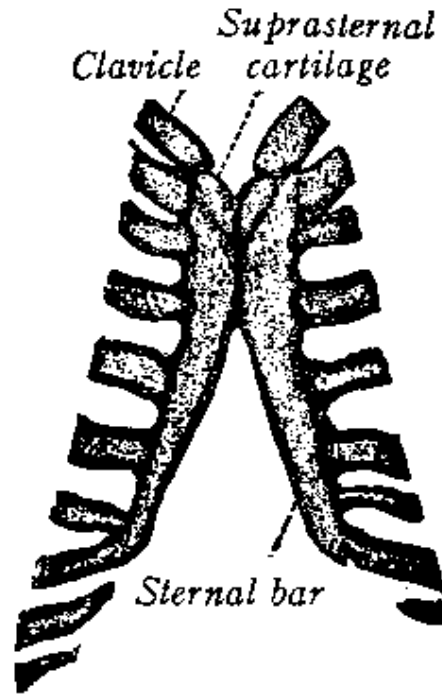
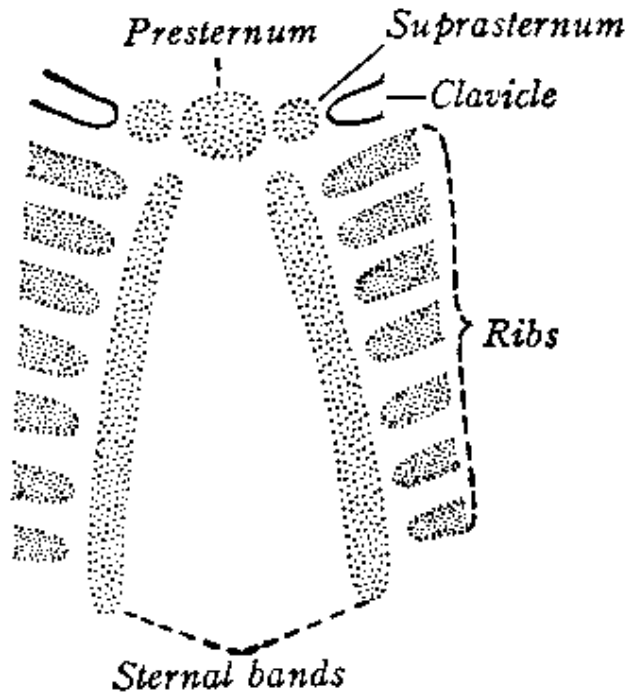
Zacharias Zachariou

KINDERKLINIKEN
Bern

Department of Paediatric Surgery
University of Berne

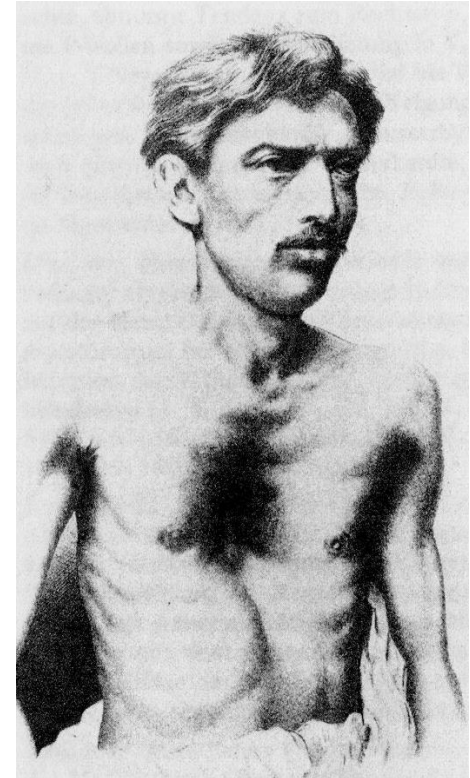


Embryology / Chest Wall Formation



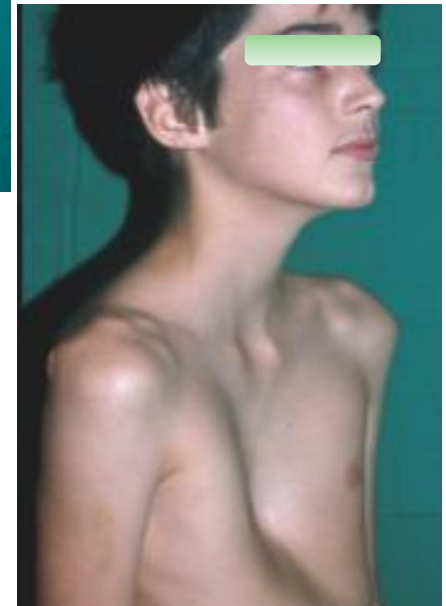
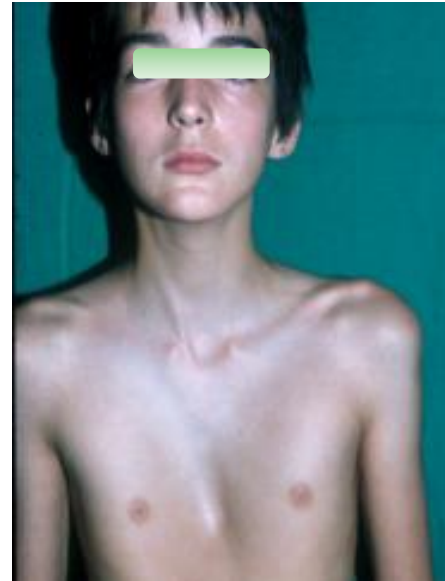Diseases of the Chest Wall

- Chest wall defects
 - Sternum clefts
- Chest wall deformities
 - Funnel chest
 - Pigeons breast
 - Costal malformations
 - Chest muscle deformities
- Diseases of the mammillae in childhood
- Tumors of the chest wall



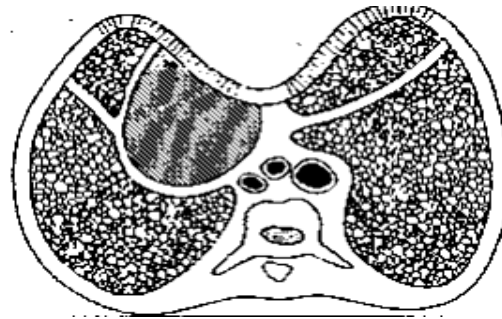
Chest Wall Deformities

- Funnel chest
- Pigeons breast
- Costal malformations
- Chest muscle deformities

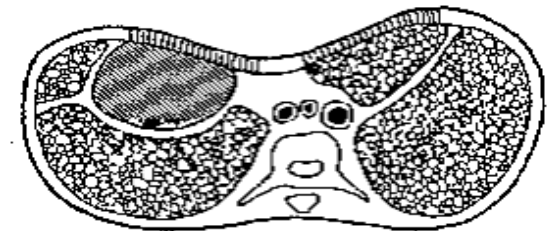


Funnel Chest / Pectus Excavatum Forms

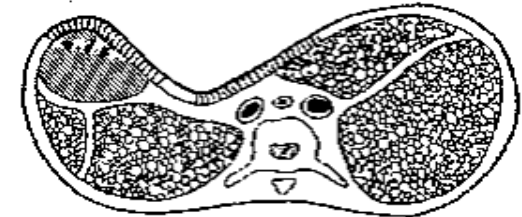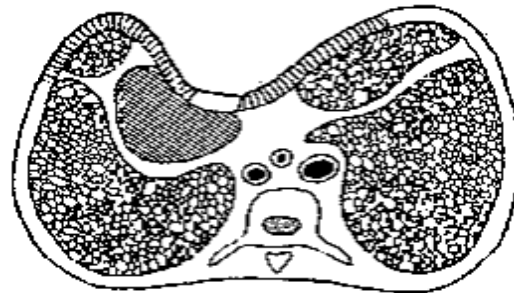
Symmetrical



Platythorax



Asymmetrical



Funnel Chest / Etiology

Old Theories (not valid):

- Intrauterine pressure
- Airways obstruction
- Rachiotis
- Lues
- Diaphragmatic malformations
- Abnormal tendinial centre
- Disharmonic growth

Current Theories:

- Mesenchymal dysgenesis
- Sternal dysplasia
- Malfunction of the Osteochondrogenesis
- Chondral metabolism defect

Funnel Chest / Related Diseases

Congenital Diseases

- Micrognathia
- Arachnodaktylia
- Hip dysplasia
- Heart diseases
- Diaphragmatic hernia

Associated Syndromes (1%)

- Poland
- Rubinstein
- Noonan
- Aarskog
- Rossi

Acquired Diseases ??

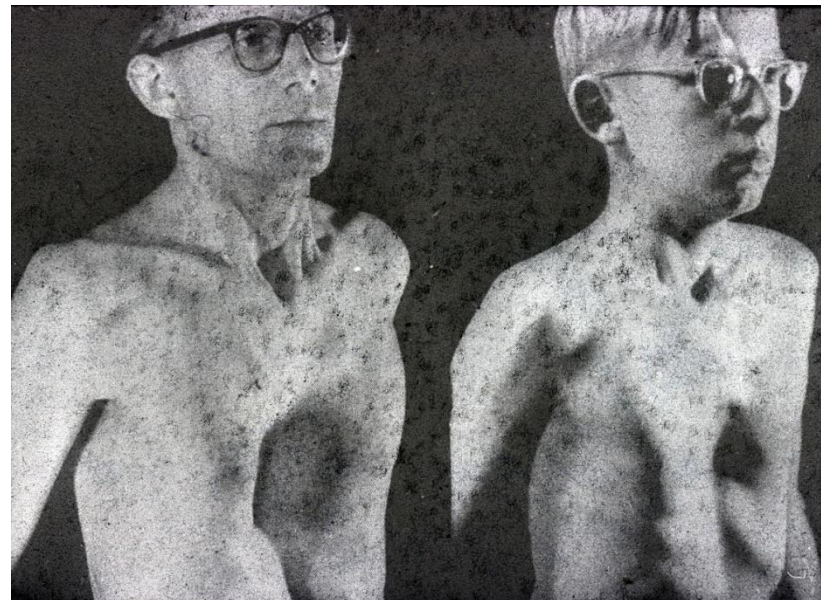- Kyphoskoliosis

Funnel Chest / Epidemiology

Inzidenz 0,059% - 2,3% of the population

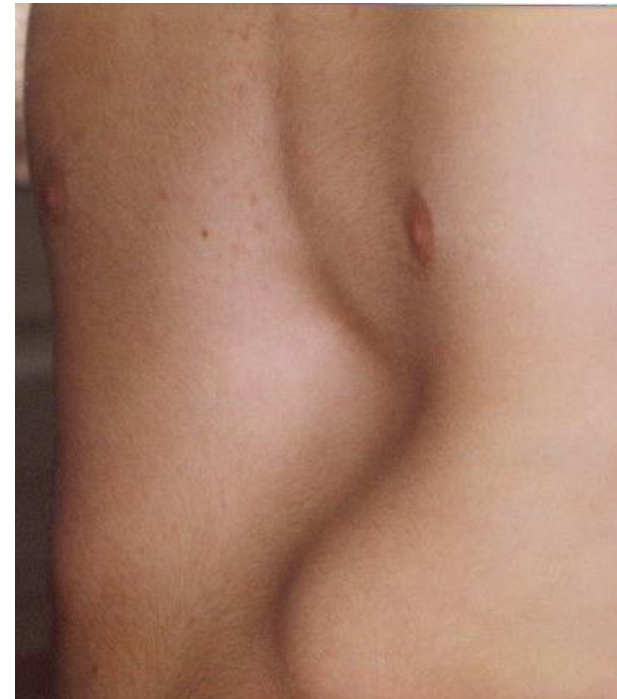Gender distribution m : f = 4 : 1

Hereditary presentation 18% - 39,3%

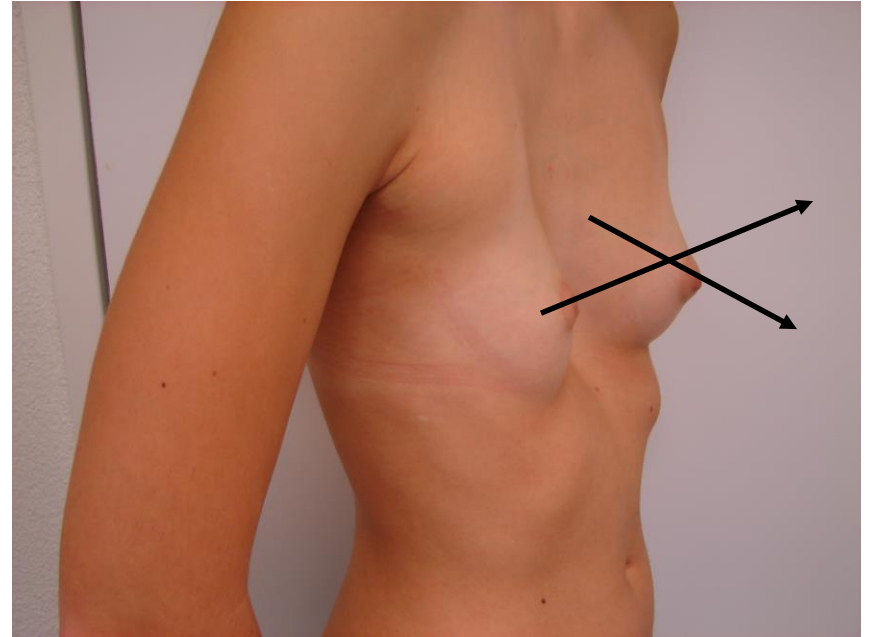
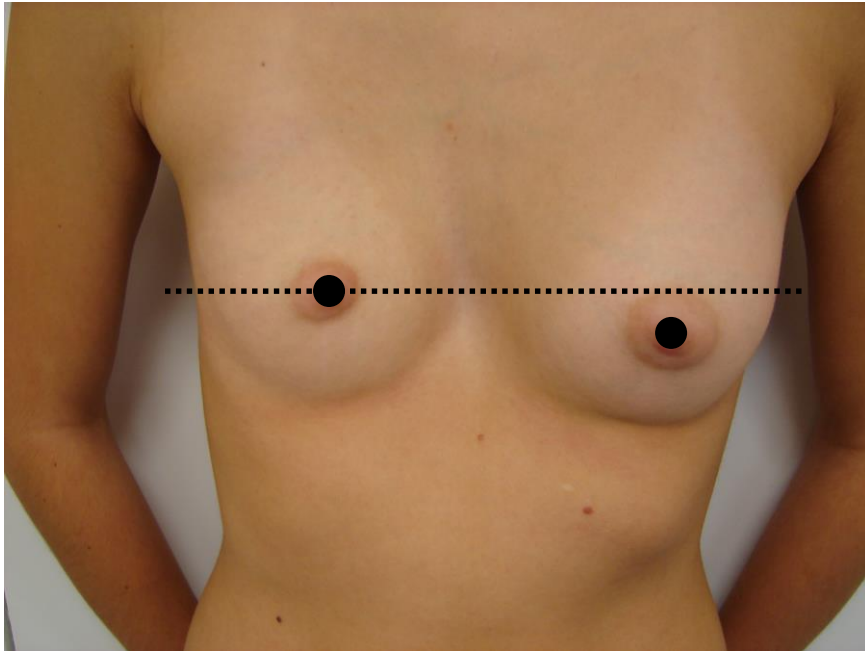


Funnel Chest / Subjective findings

- Short of breath after exercise
- Heart sensations
- Chest constriction
- Quick exhaustion
- Dizziness
- Airway infections



Funnel Chest / Problem in girls

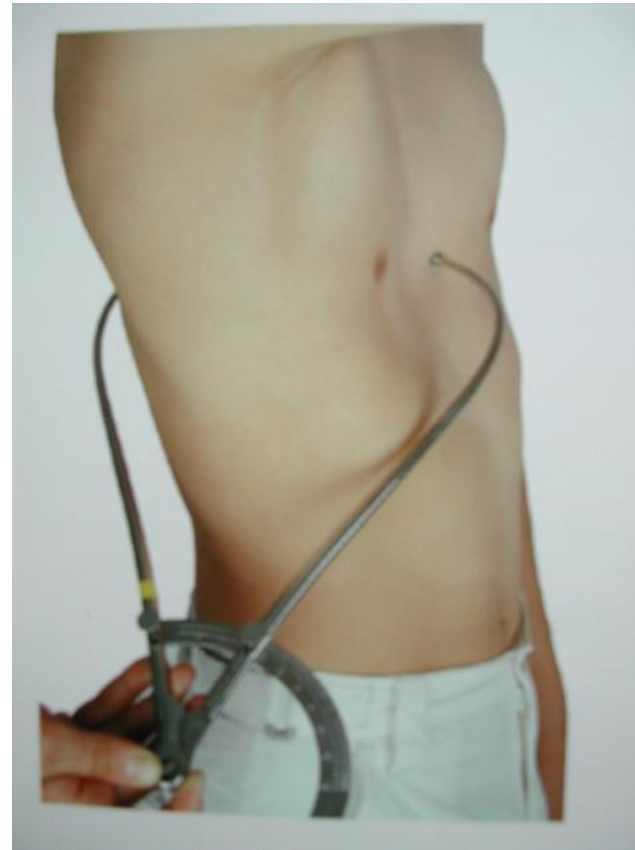
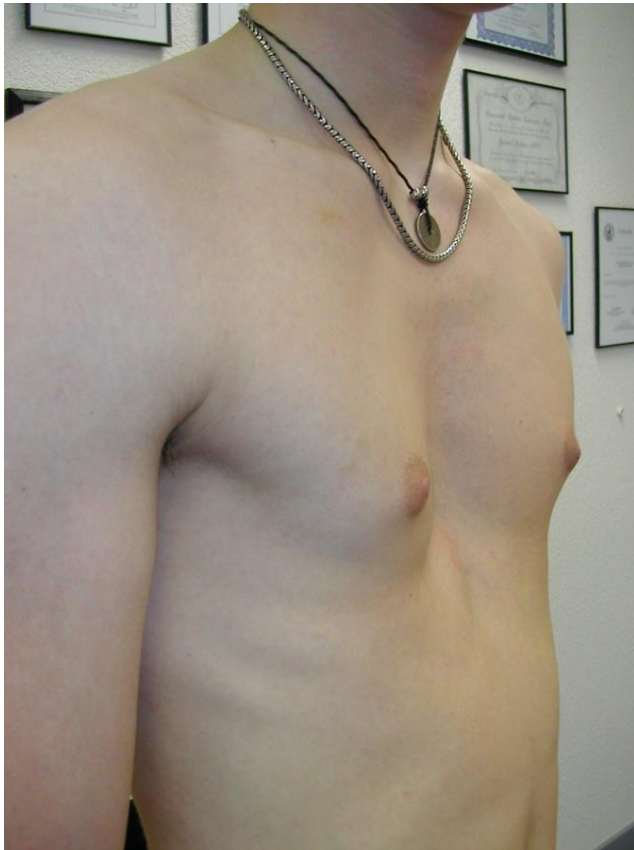
Funnel Chest / Diagnostics

- Clinical evaluation including measurements and photo
- History including objective problems for daily work
- Chest X-Ray in 2 planes
- ECG
- Lung function tests
- CT / MRI / 3D-processing
- Psychological evaluation

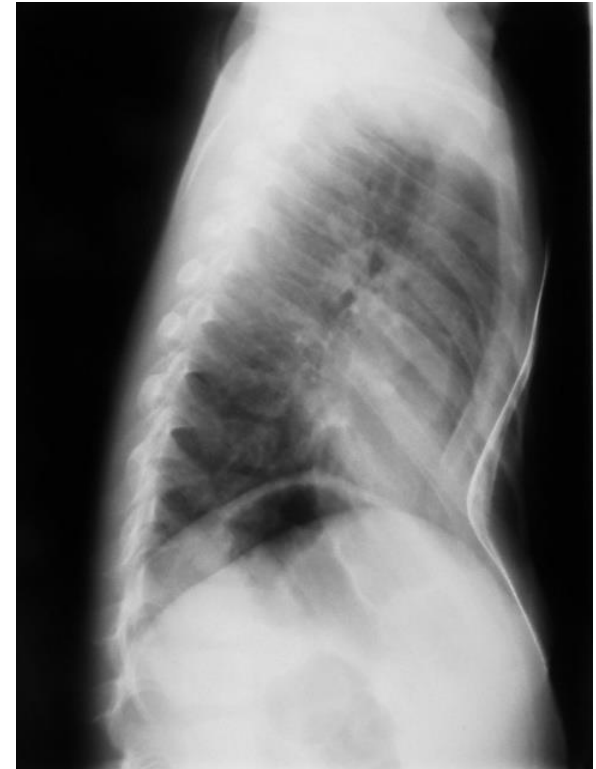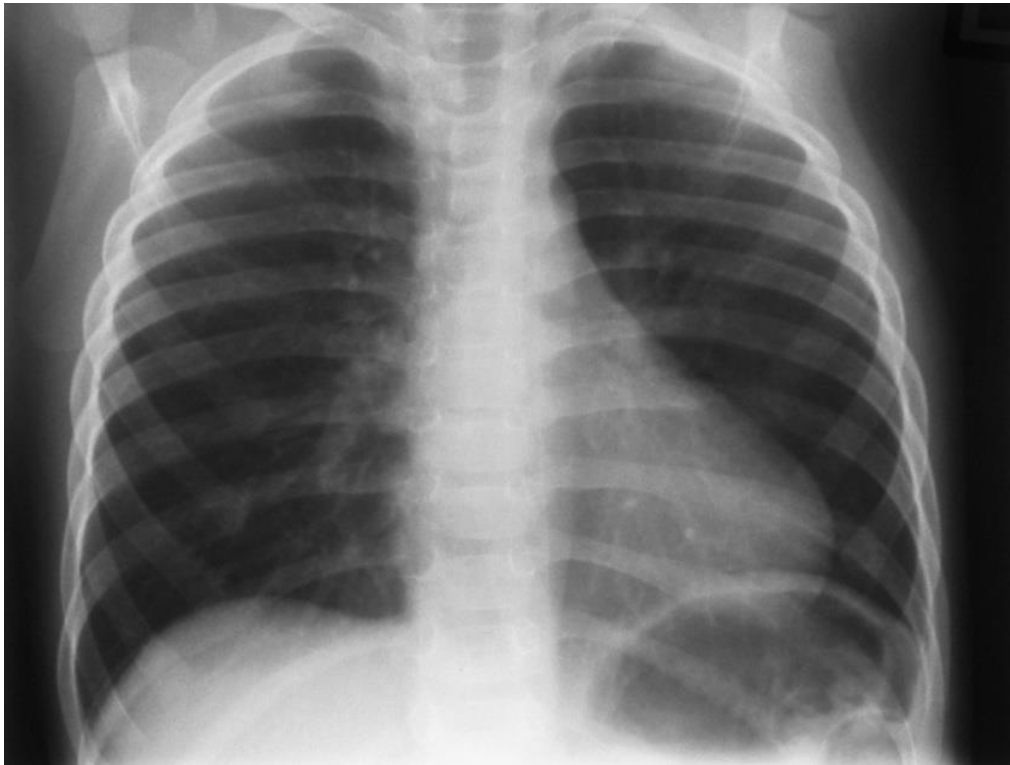
Funnel Chest / Diagnostics

Clinical evaluation including measurements and photo



Funnel Chest / Diagnostics

Chest X-Ray in 2 planes



Funnel Chest / Diagnostics

Chest X-Ray in 2 planes

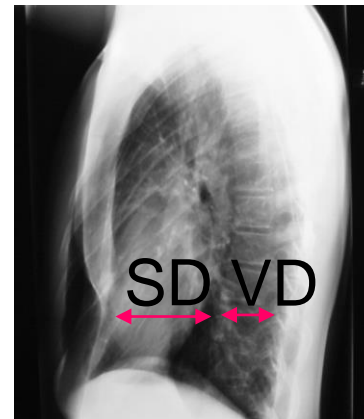
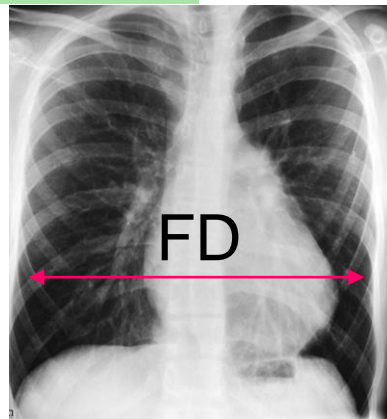
Backer Indices

$$\text{Fronto-sagittal Index (FSI)} = \frac{\text{Sagittal diameter} \times 100}{\text{Frontal diameter}}$$

36-56

$$\text{Vertebral Index (VI)} = \frac{\text{Vertebral diameter} \times 100}{\text{Sagittal} + \text{Vertebral diameter}}$$

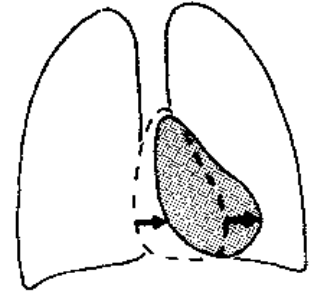
15-25



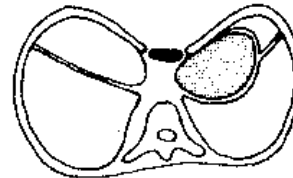
Funnel Chest / Diagnostics

Lung function tests

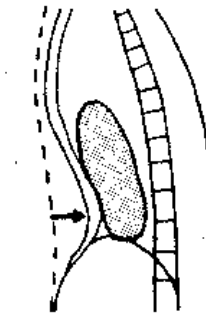
Heart dystopia



Frontal constriction



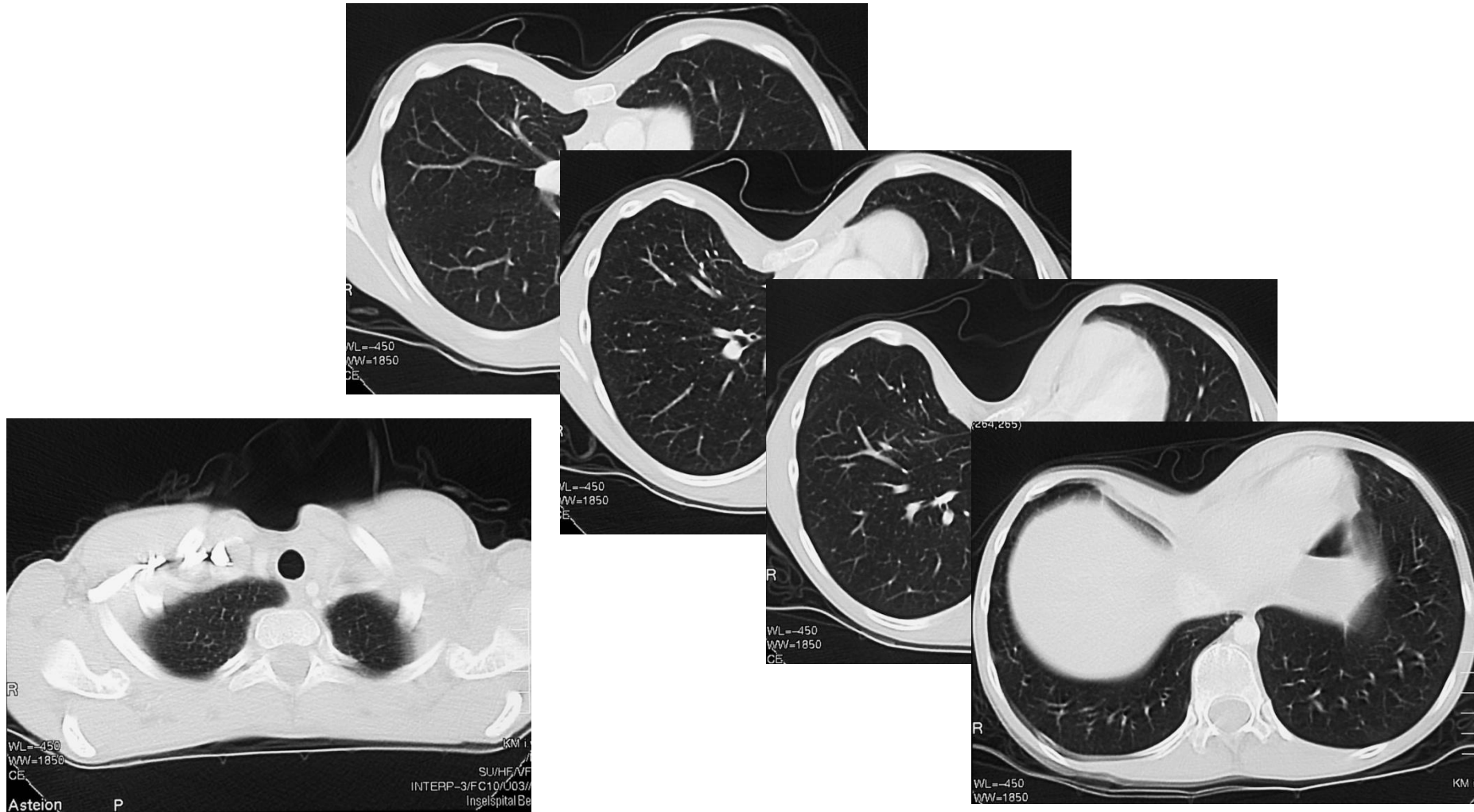Sagittal constriction



Lung volume reduction

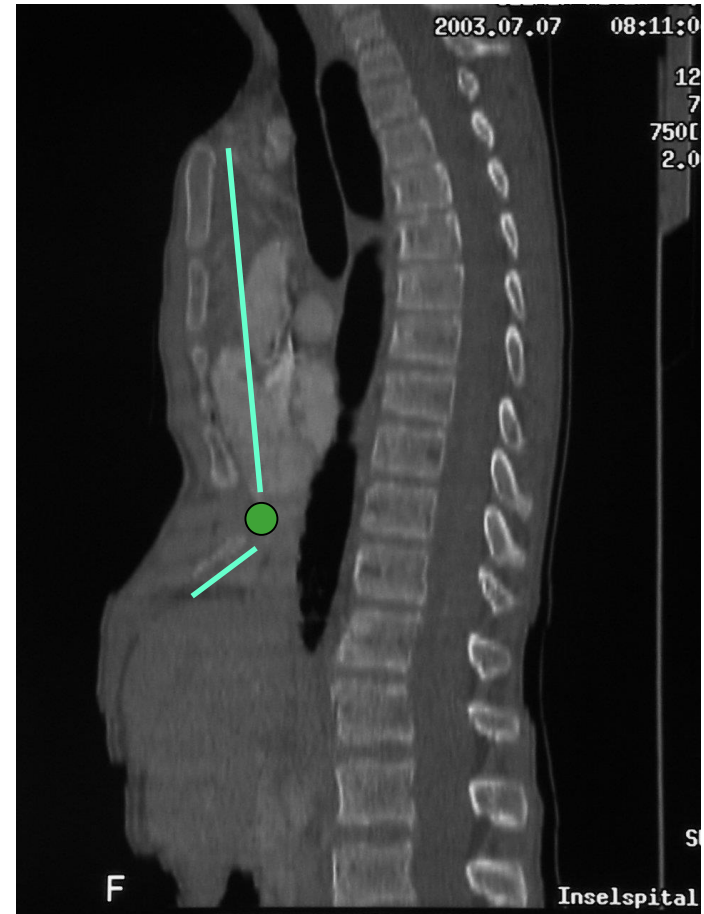
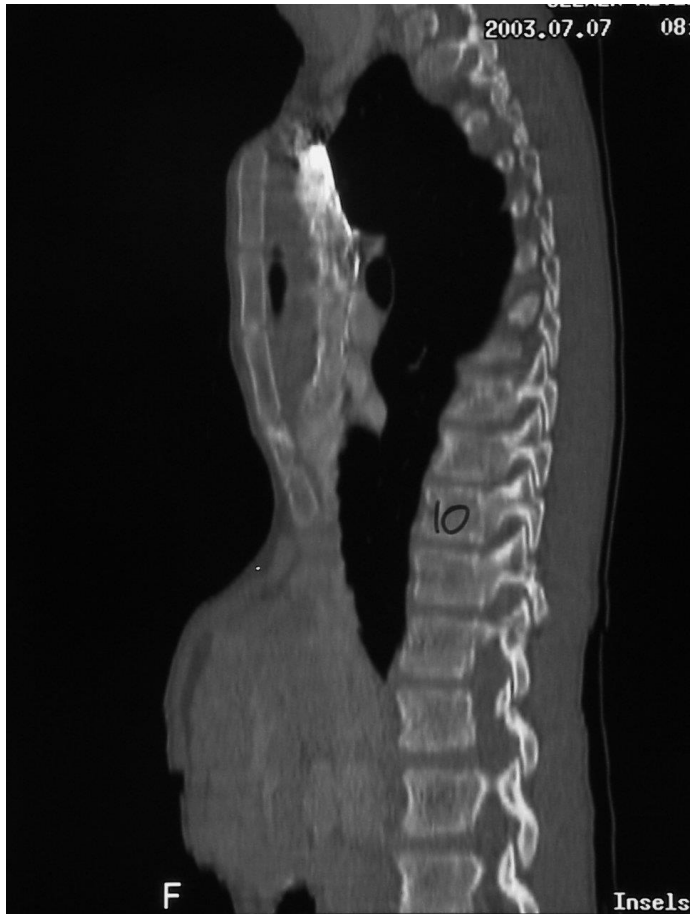Funnel Chest / Diagnostics

CT / MRI



Funnel Chest / Diagnostics

MRI

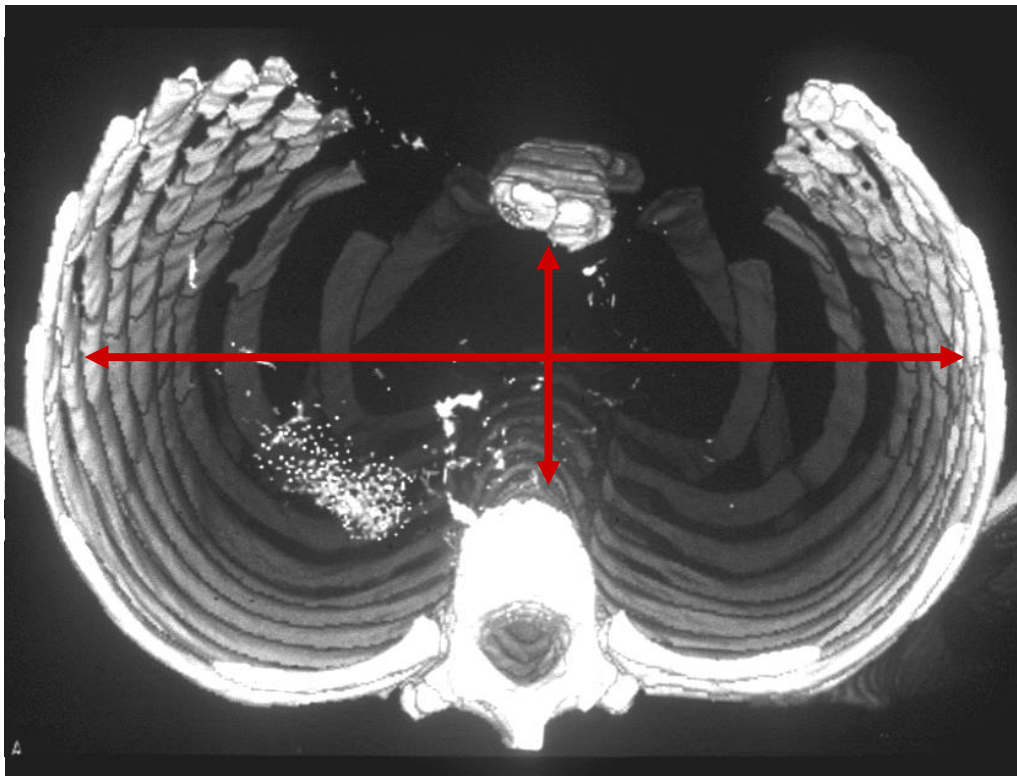


Funnel Chest Diagnostics

CT / MRI / 3D-processing

$$\text{Haller Index} = \frac{\text{Frontal diameter}}{\text{Sagittal diameter}}$$

< 3.24



Funnel Chest / Diagnostics

Psychological evaluation

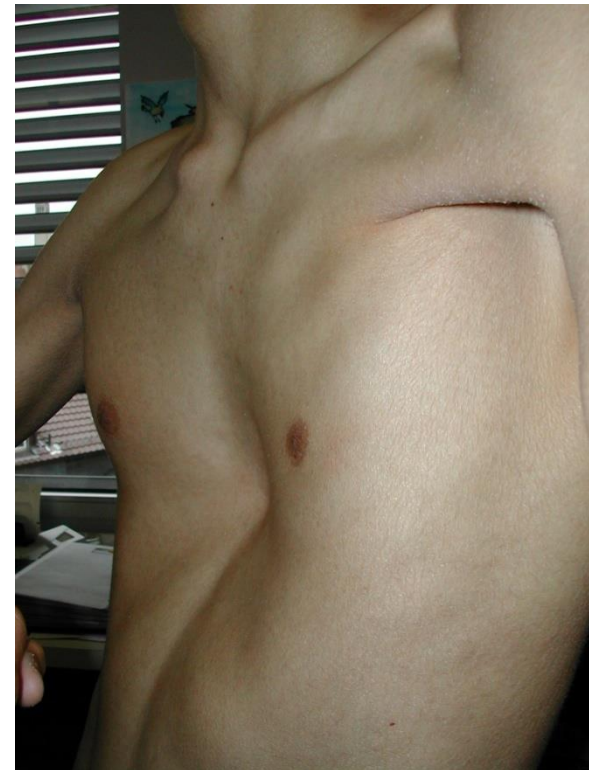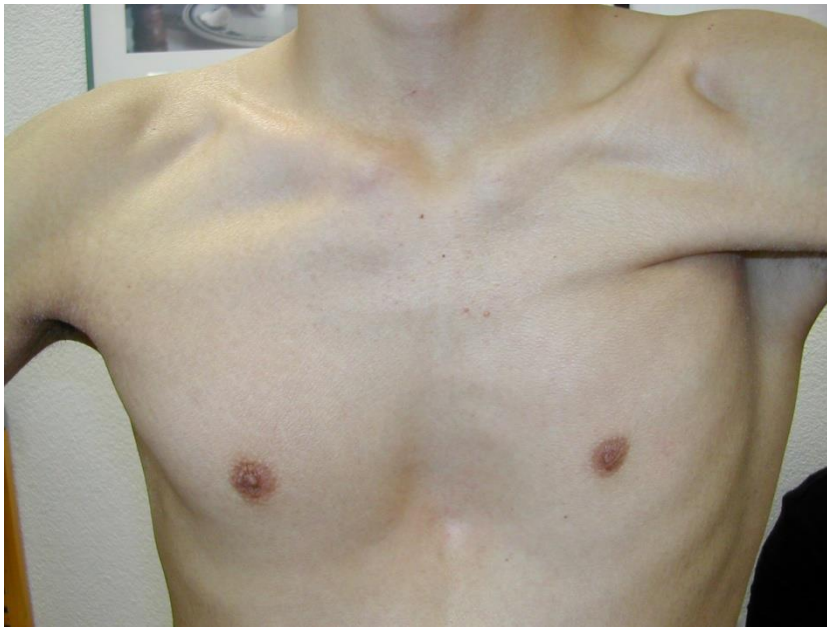
- Psychological strain
- Embarrassed in public
- Stigmatized
- Depressed
- In preparation for the operation

Funnel Chest / Therapy

- Physical management
- Conservative management
- Surgical management

Funnel Chest / Therapy

- Physical management
- Conservative management
- Surgical management



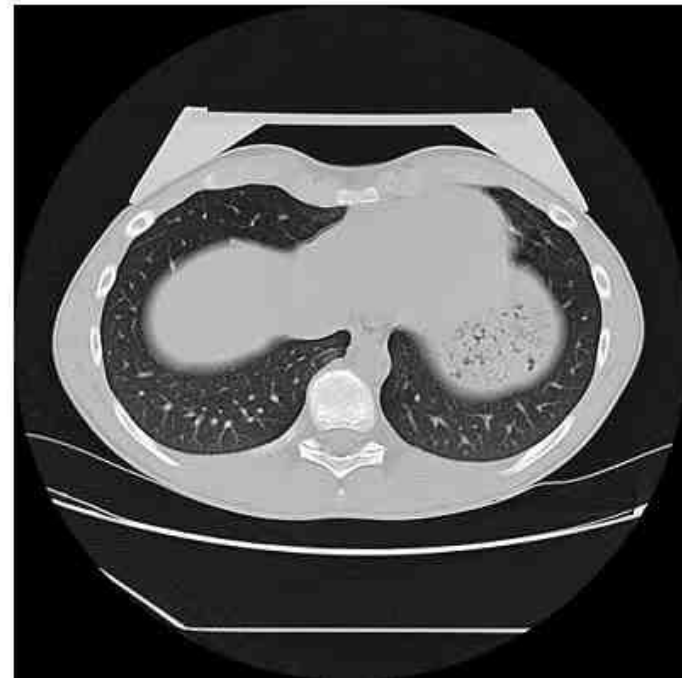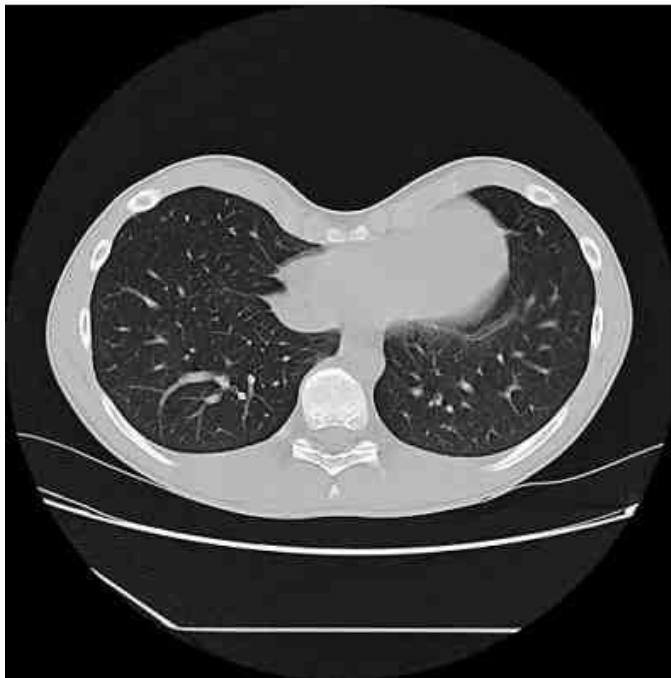Funnel Chest / Therapy

- Physical management
- Conservative management
- Surgical management



Funnel Chest / Therapy

- Physical management
- **Conservative management**
- Surgical management



Funnel Chest / Therapy

Surgical intervention (medical reasons)

- Cardiac symptoms
- Pulmonary compression
- Spinal symptoms
- Sternum torsion

Surgical intervention (individual reasons)

- Psychological problems
- Cosmesis

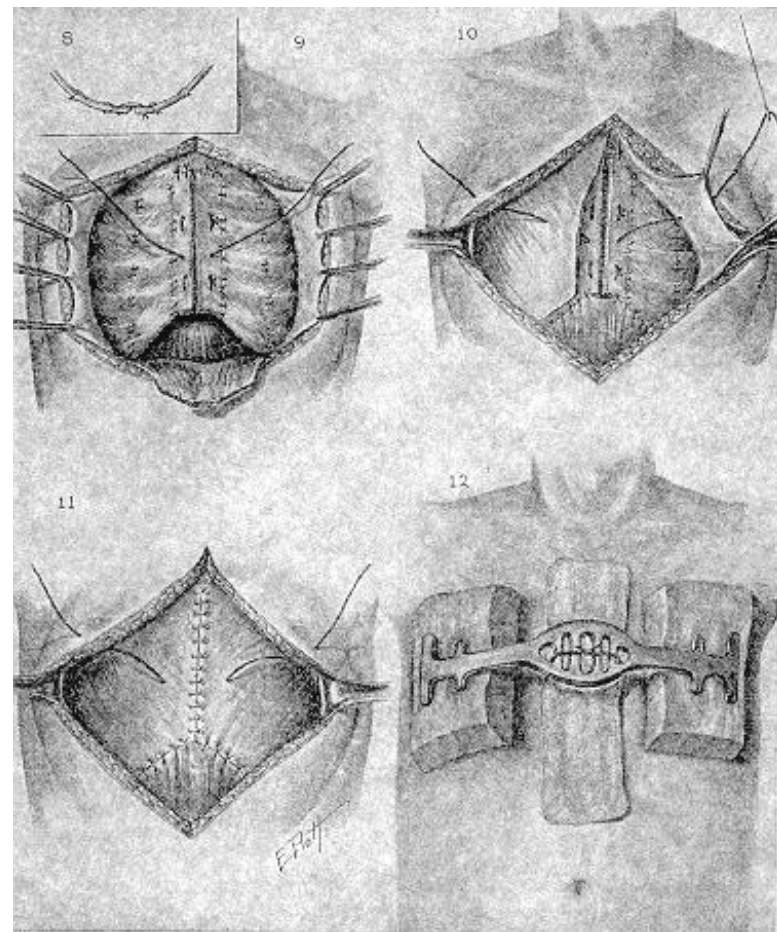
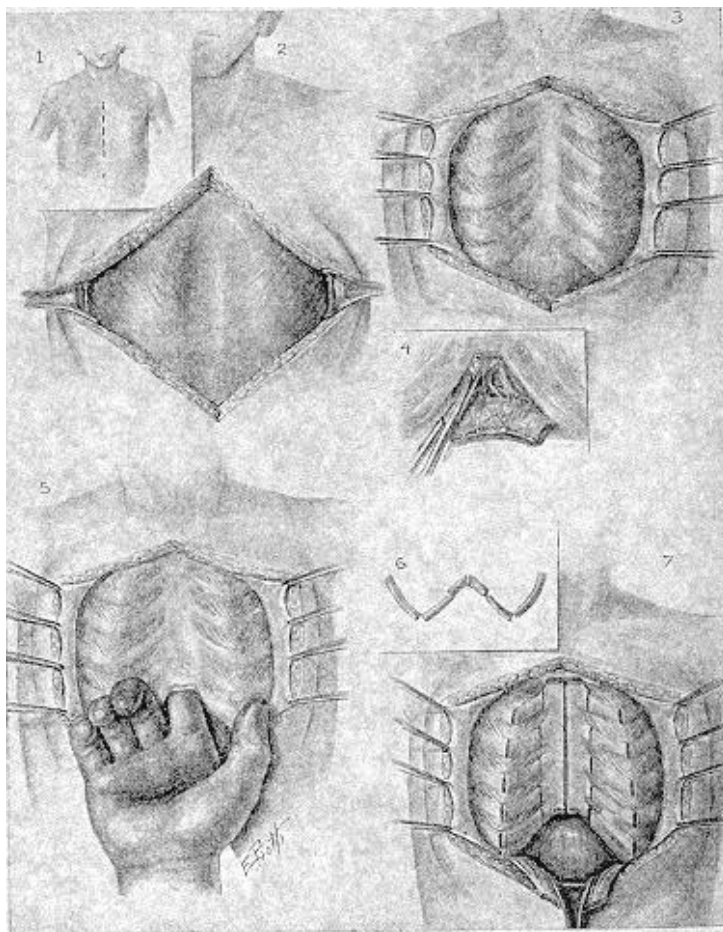
Funnel Chest / Operative Methods

1911-1920	Chondrosternal resection	Sauerbruch
1921-1939	External extension, Sternotomy	Ochsner
	Cartilage Inzision / -resection	Lester
Since 1940	Sternotomy, cartilage resection	Ravitch, Welch
Since 1950	Internal fixation, Sternotomy	Rehbein, Haller
	Cartilage Inzision / -resection	Fonkalsrud
Since 1980	Bar Implantation	Nuss

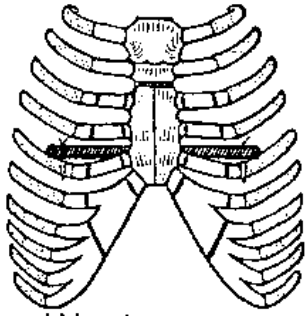
Funnel Chest / Operative Methods

1921-1939 Lester

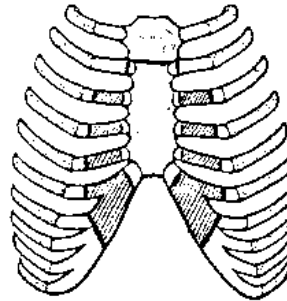
External extension, Sternotomy, Cartilage Inzision / -resection



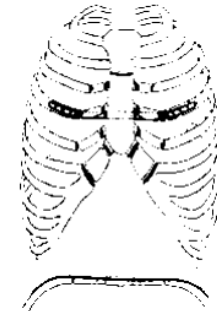Funnel Chest / Operative Methods



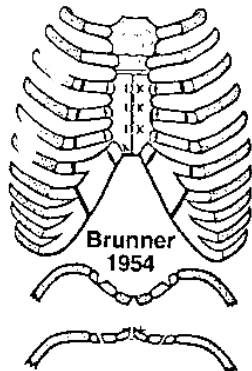
Wanke 1953
Adkins 1958



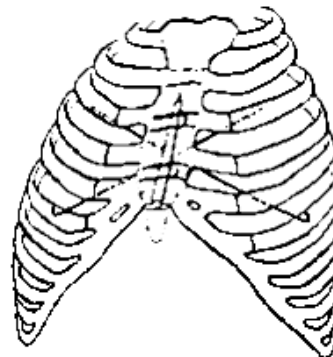
Ravitch
1949/1964
Welch



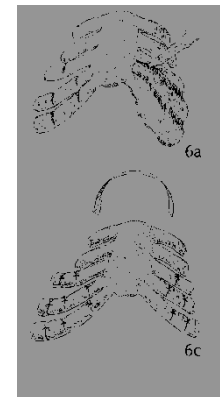Hegemann
Willital
Hummer



Brunner 1954

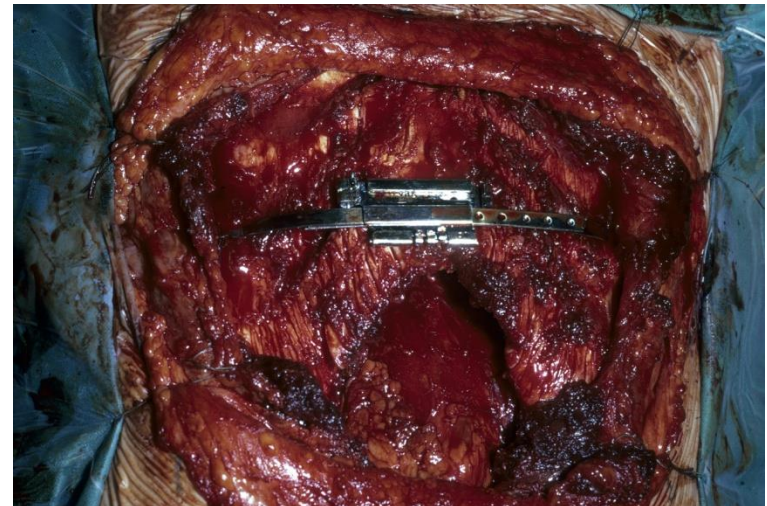
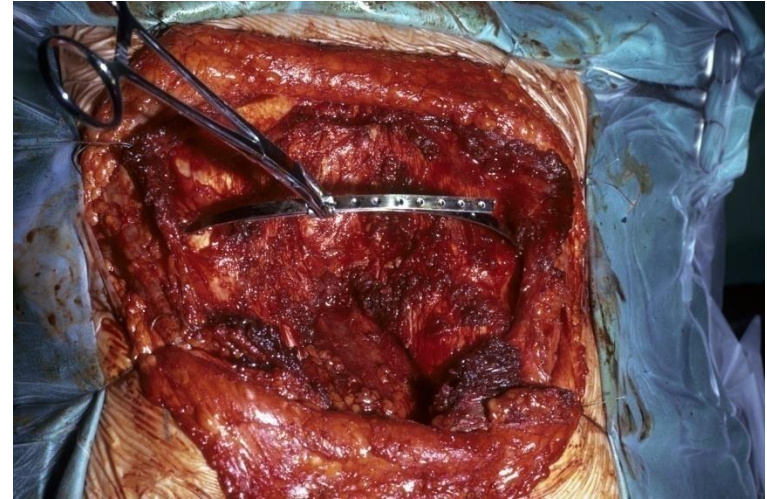
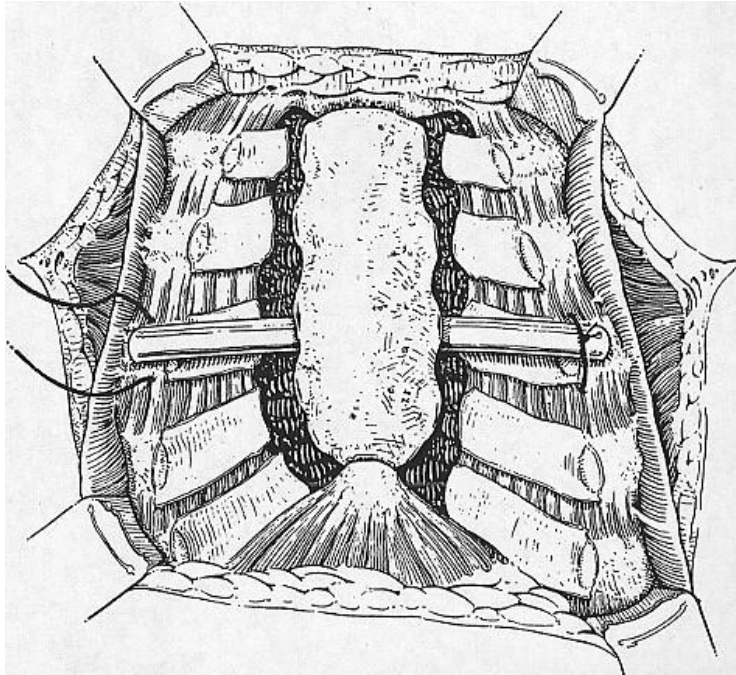


Grob 1957
Übermuth 1957
Schautz 1966

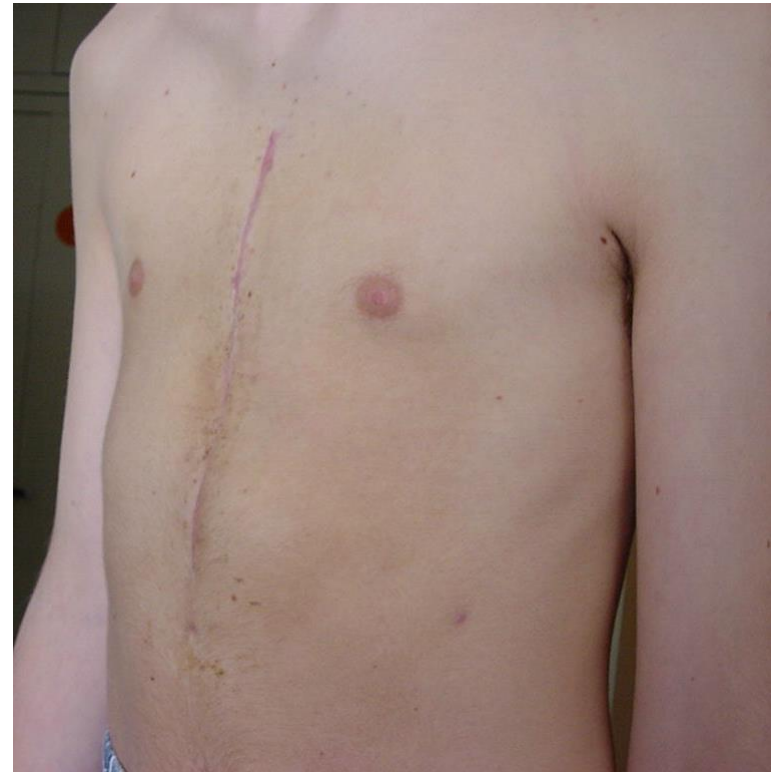
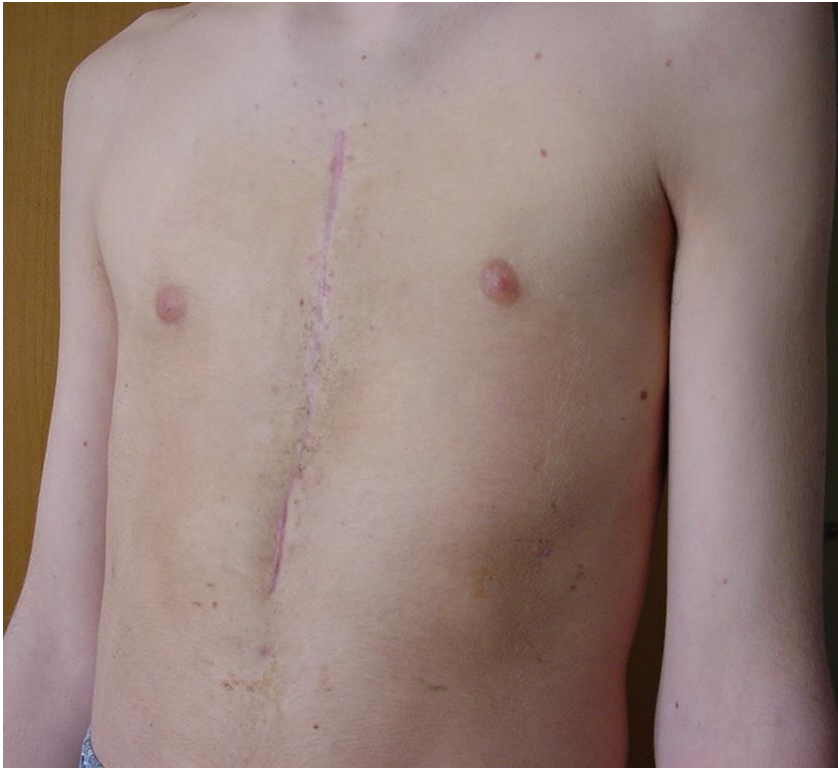
„turnover“

Funnel Chest / Ravich Procedure

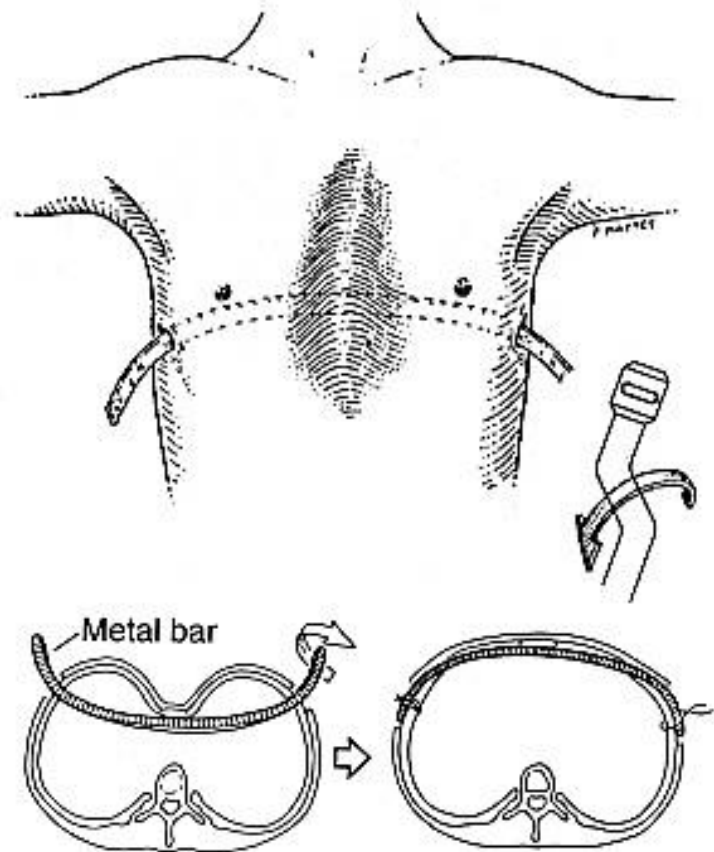


Funnel Chest / Ravich Procedure Results

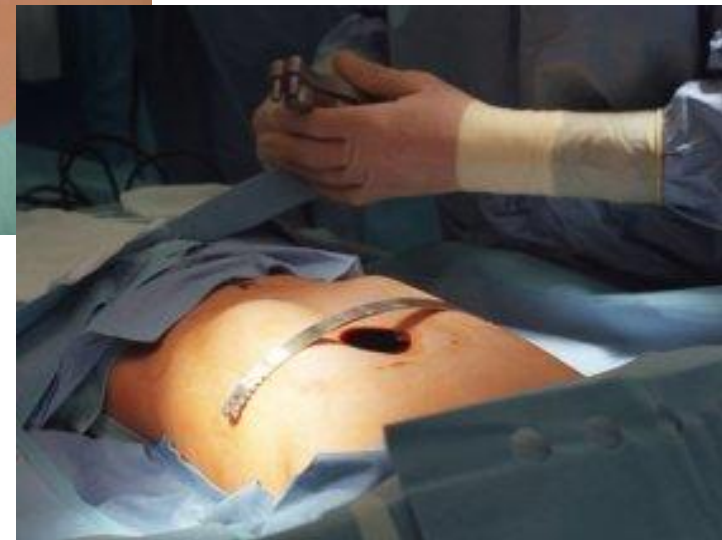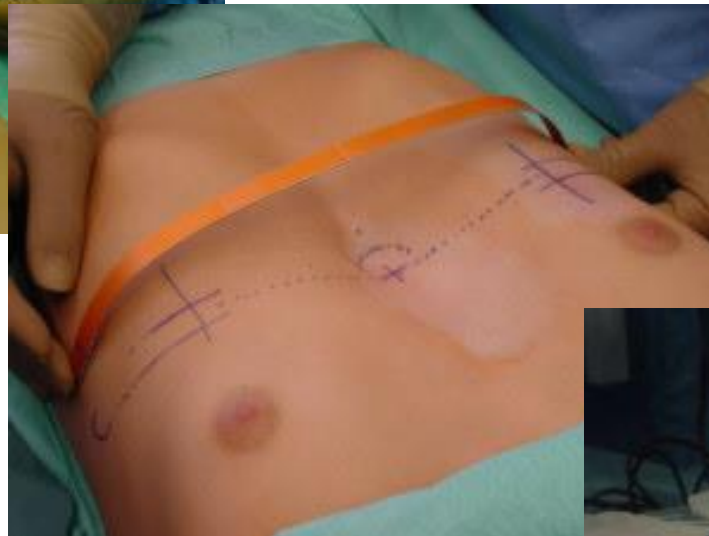

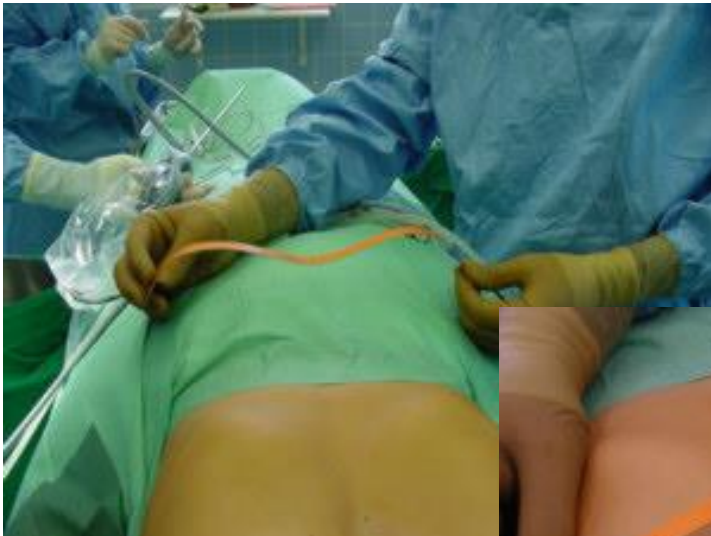
Funnel Chest / Nuss Procedure

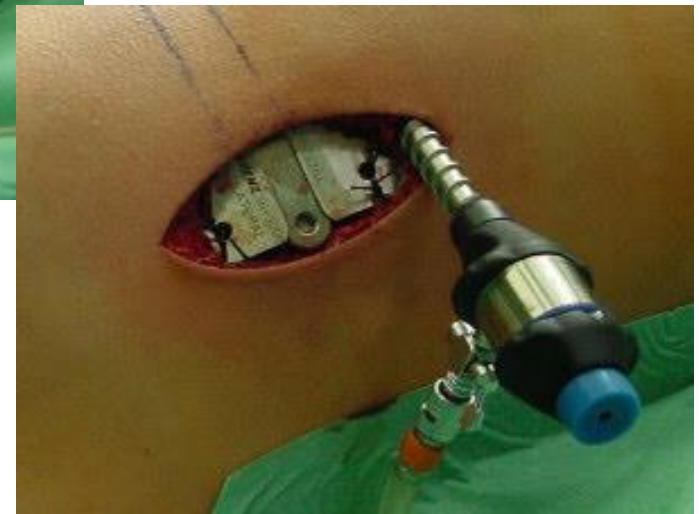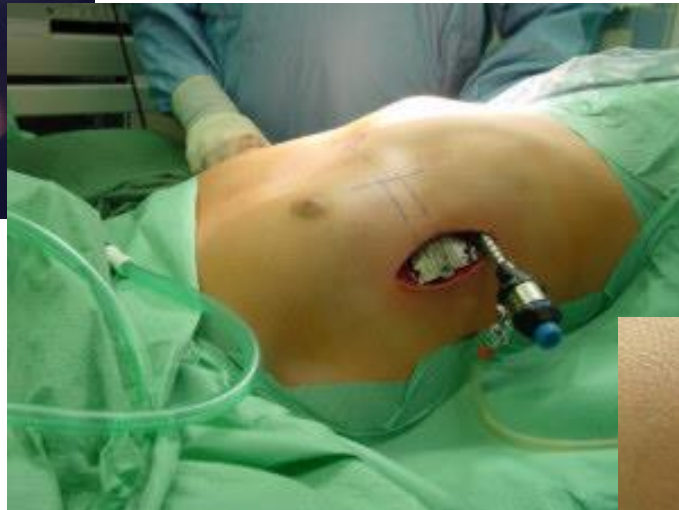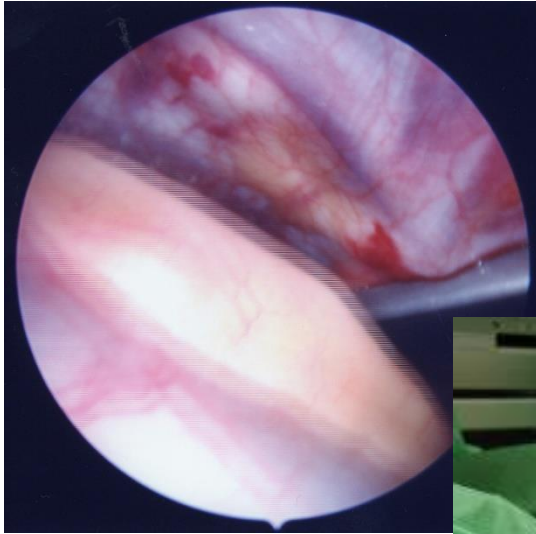
The Nuss Minimal Invasive Procedure



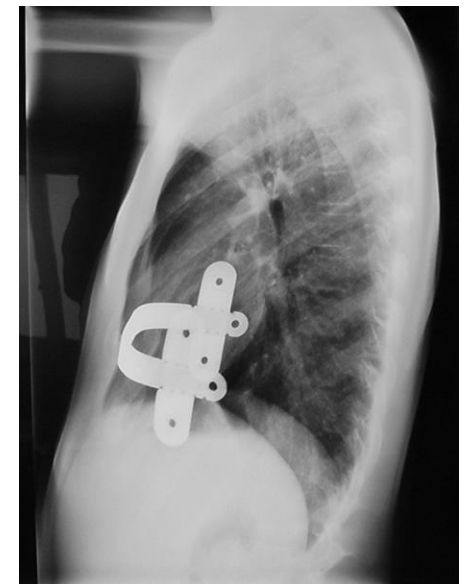
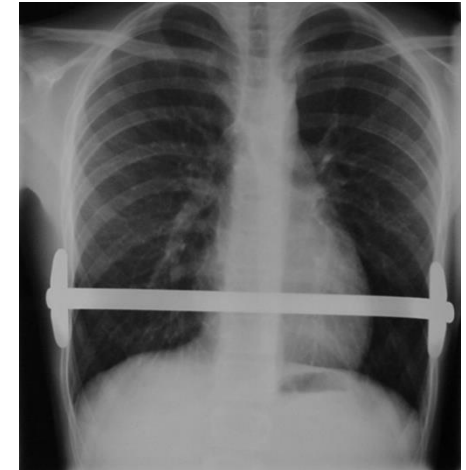
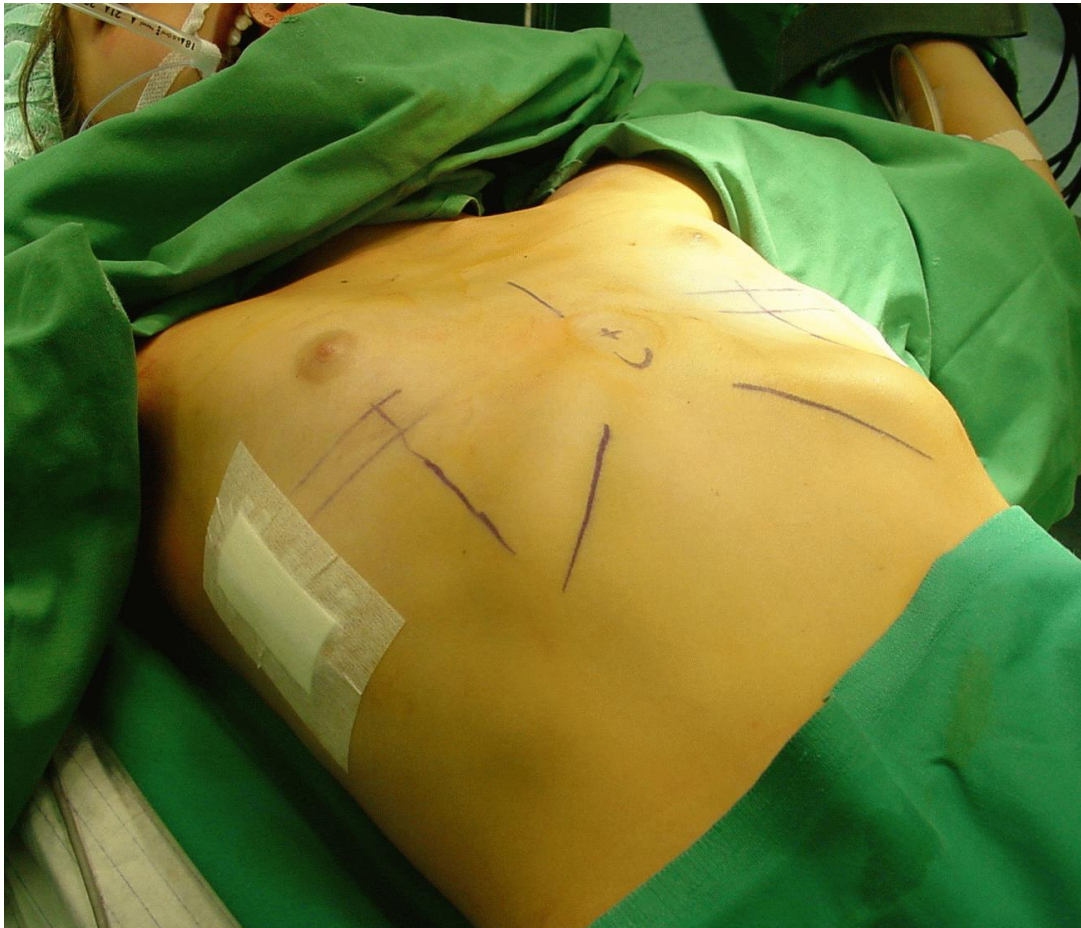Funnel Chest / Nuss Procedure



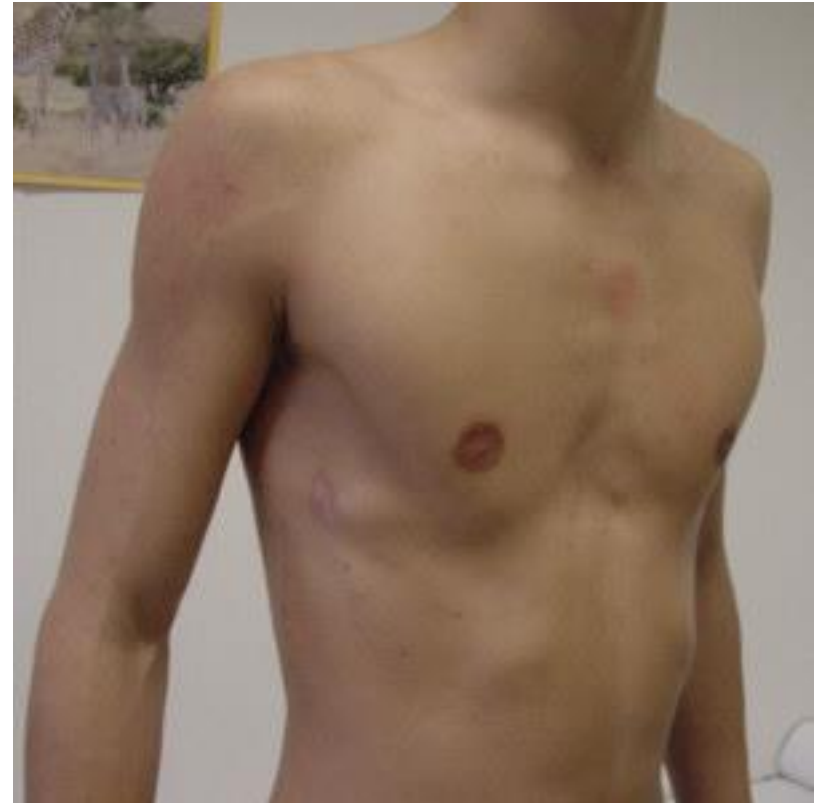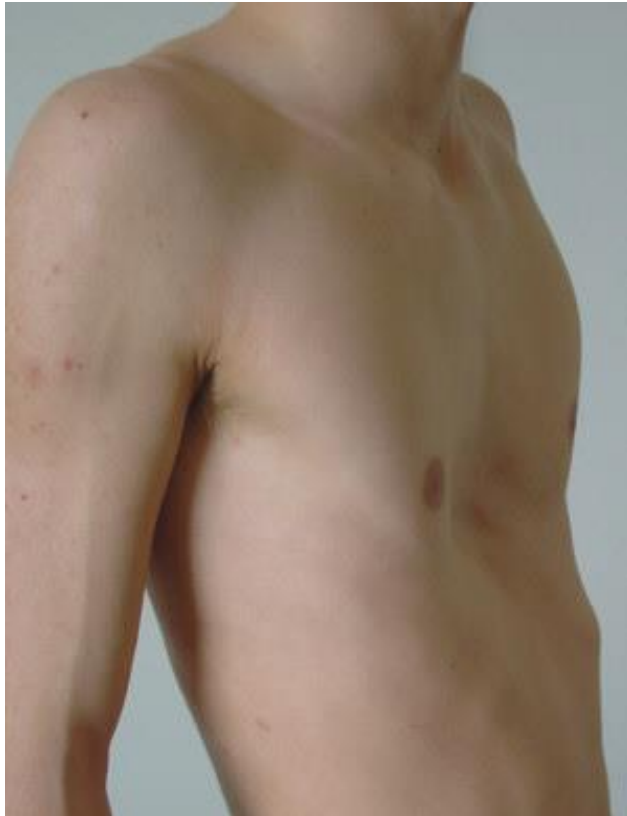Funnel Chest / Nuss Procedure



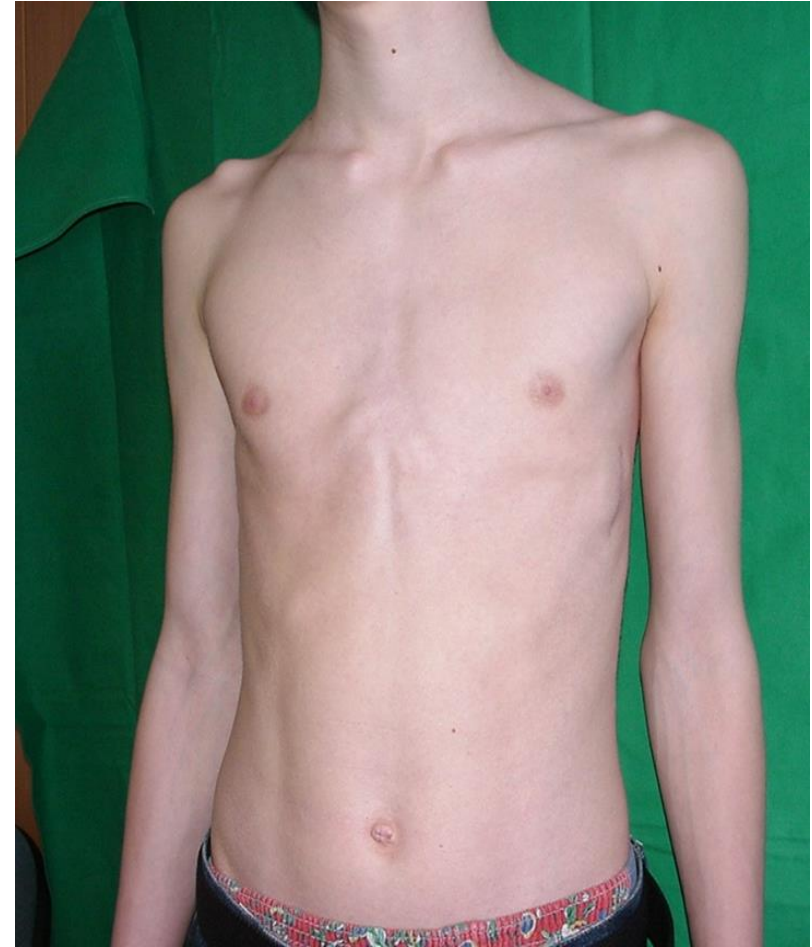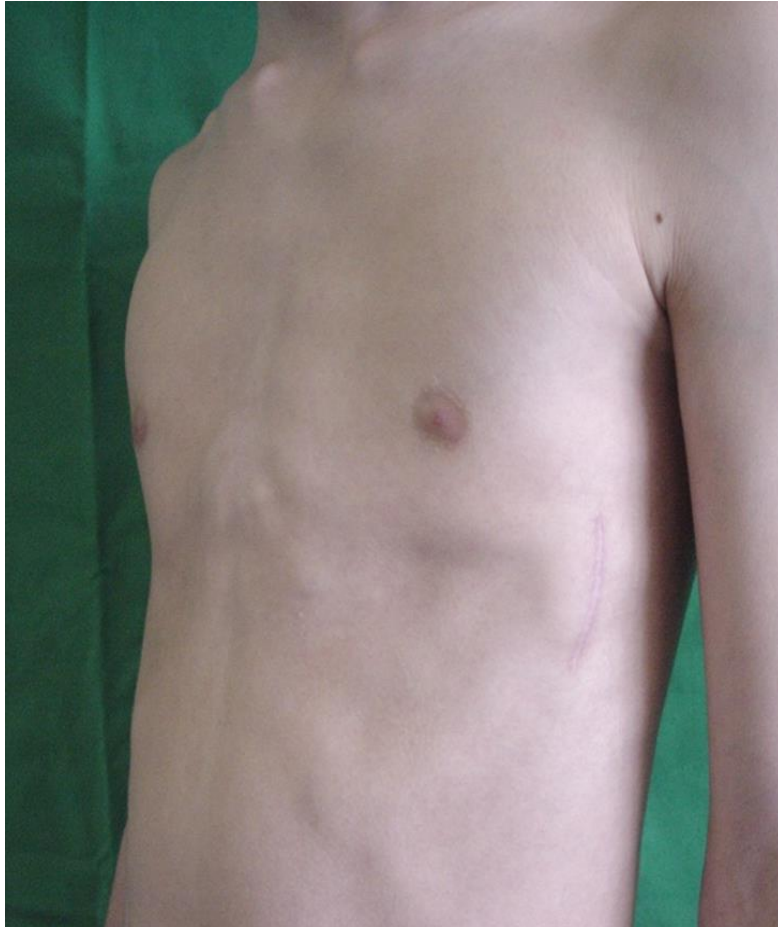Funnel Chest / Nuss Procedure



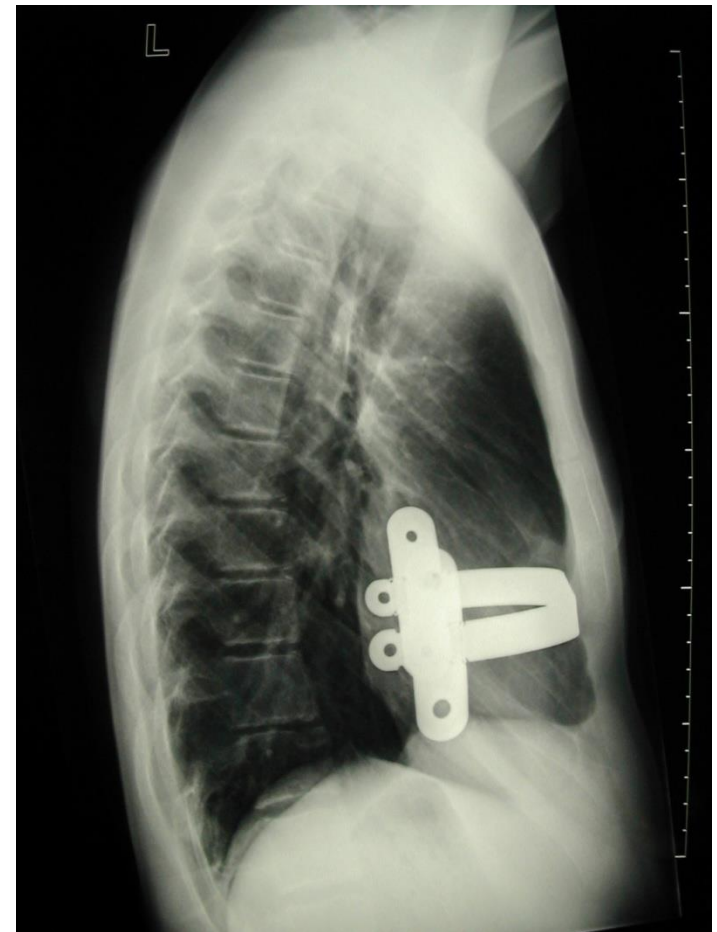
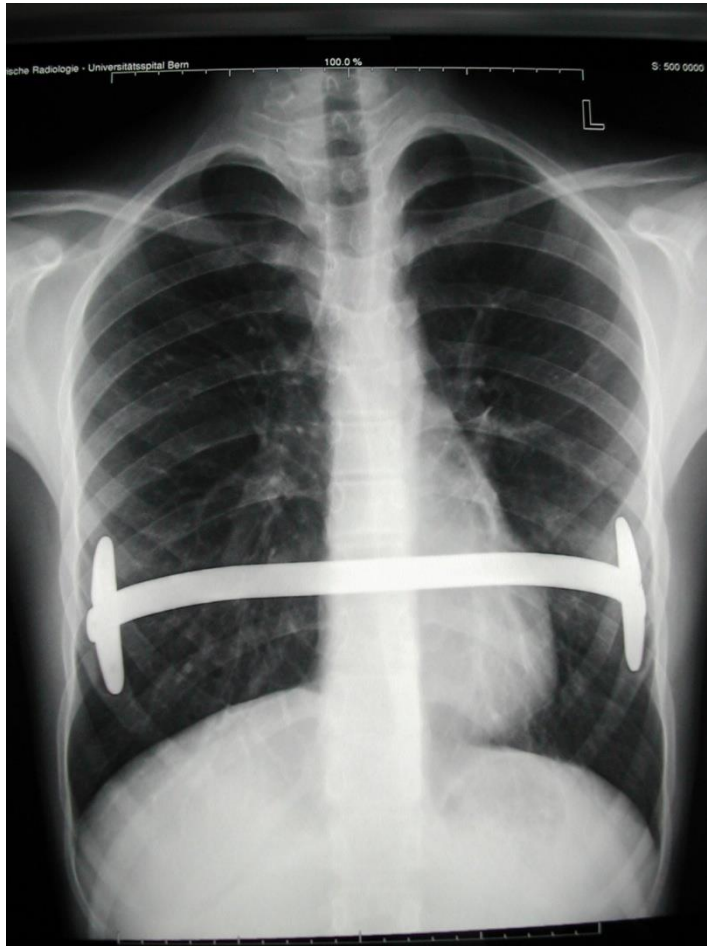
Funnel Chest / Nuss Procedure Results



Funnel Chest / Nuss Procedure Results

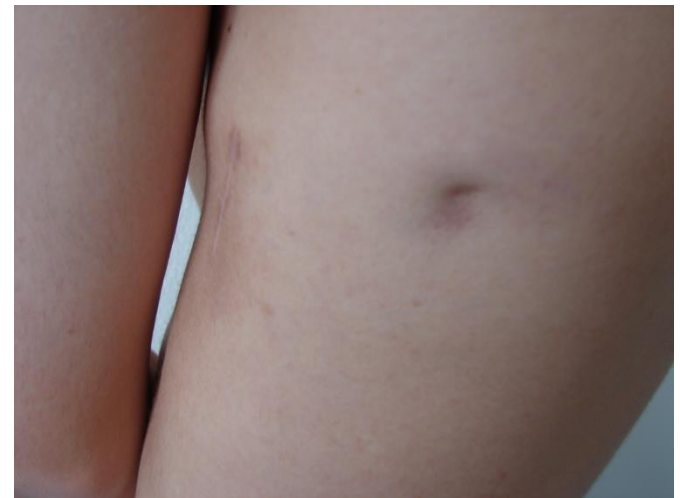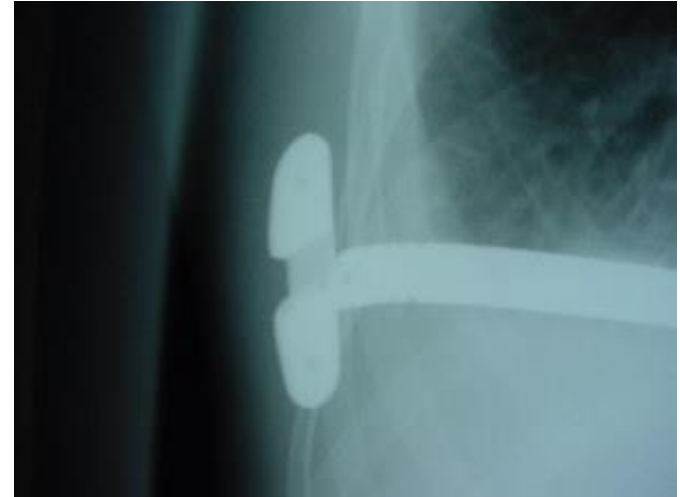


Funnel Chest / Nuss Procedure Results



Funnel Chest / Nuss Procedure Complications

- Dislocation of the stabilisators
- Infections
- Pain
- Under correction
- Over correction

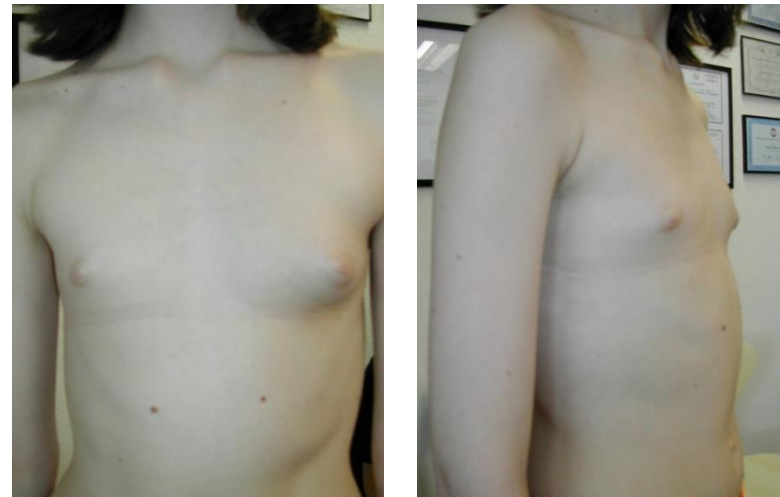
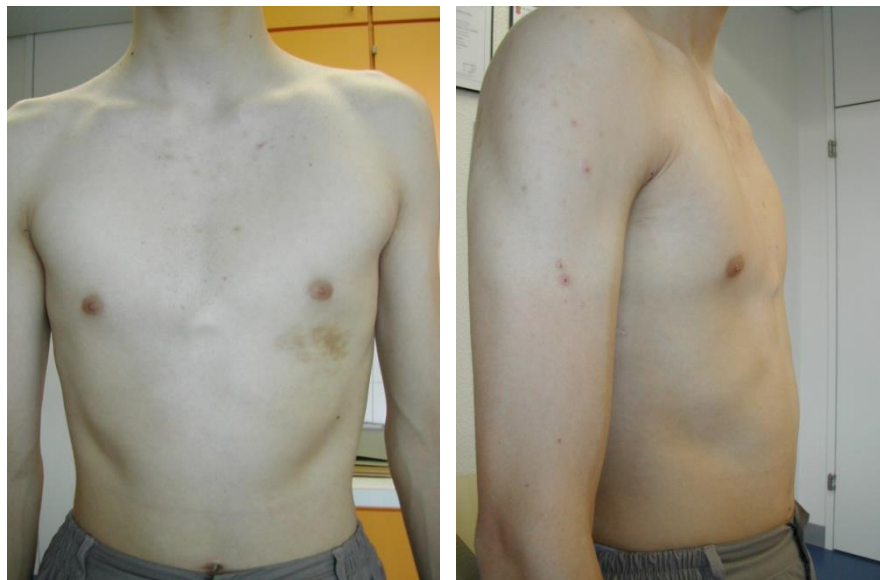
Funnel Chest / Nuss Procedure Follow-up

3,6 weeks / 6 months / yearly

Sports for better posture

- Swimming as from 3rd week
- Sports as from 1st month



Funnel Chest / Nuss Procedure Follow-up

Bar removal

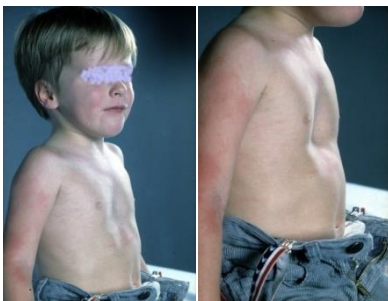
- Depending on age
- Minimum 2 yrs
- Maximum 4 yrs
- Completion of growth



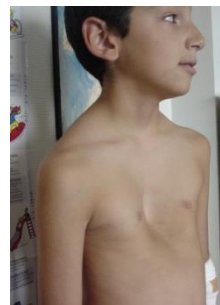Funnel Chest / Operation time

When is the right age for the Operation?

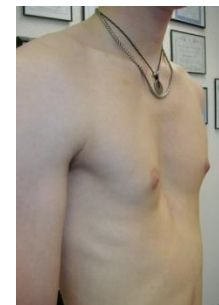
Age	< 8 yrs	8-14 yrs	>14 yrs
Number	15	128	63
Complic.	5 (33%)	17 (13%)	16 (25%)



Too early



Correct



Overhang

Funnel Chest / Operative Methods

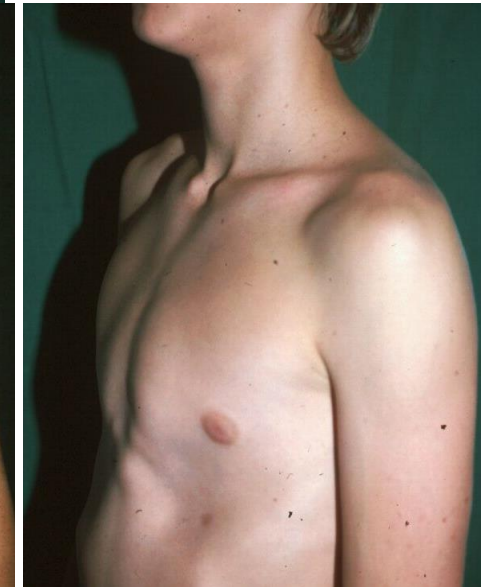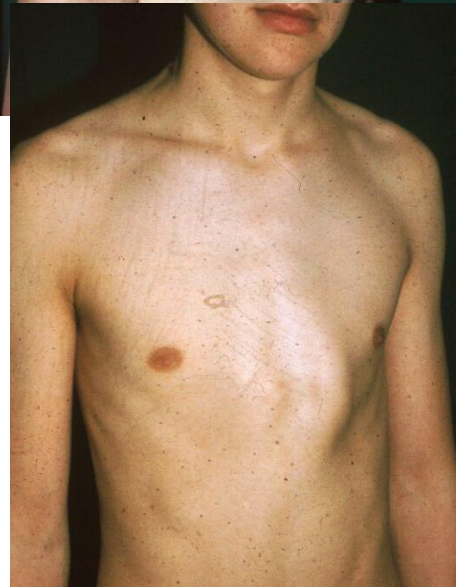
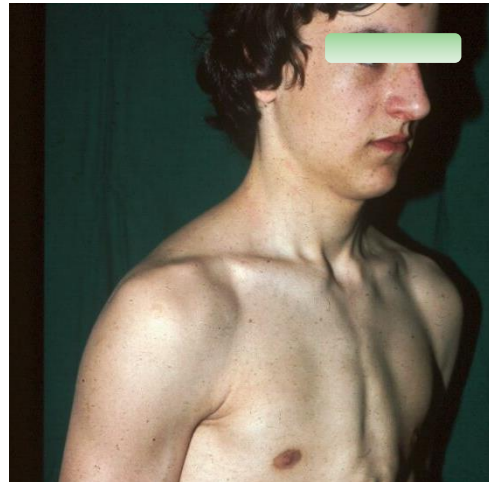
Silicon Implant

- Only cosmetic correction / Non functional
- Discussion on side effects of silicon implants

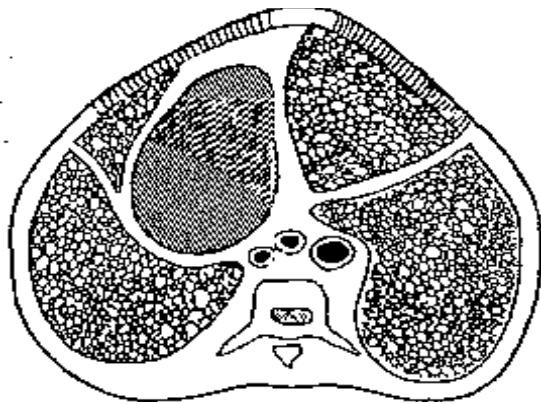
Chest Wall Deformities

Chest wall deformities

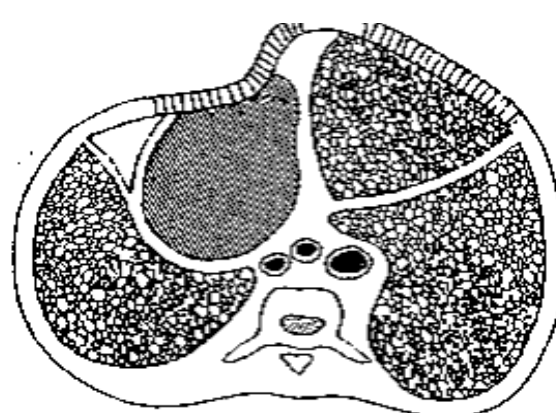
- Funnel chest
- **Pigeons breast**
- Costal malformations
- Chest muscle deformities



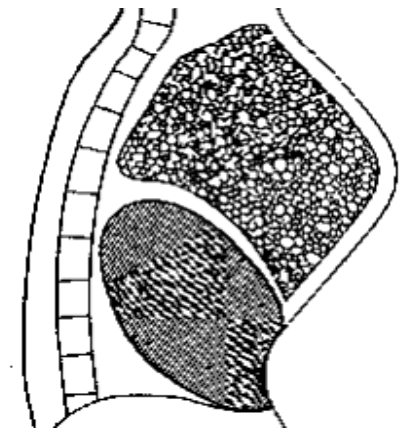
Pigeons breast / Forms



symmetrical



asymmetrical



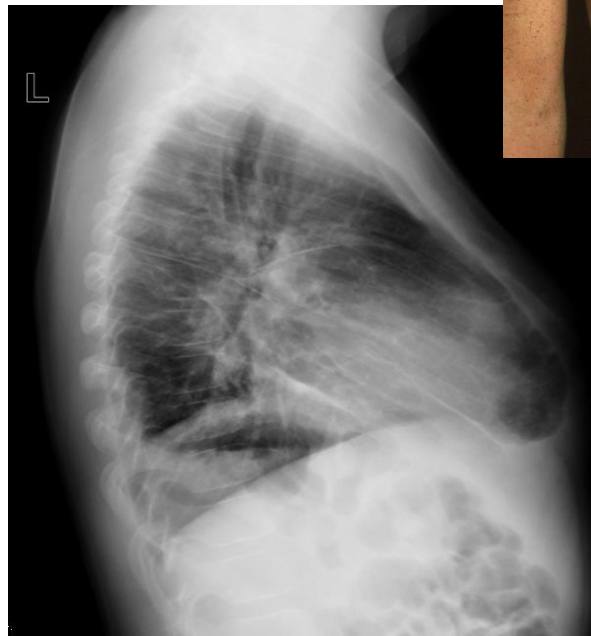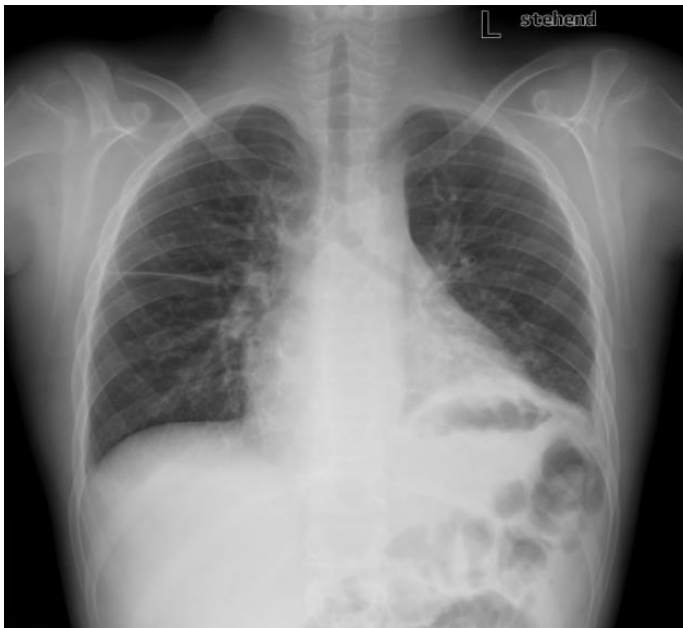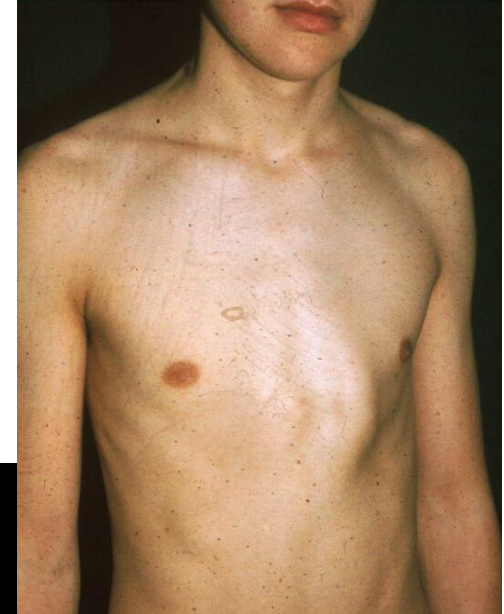
**Combination
Pigeon / funnel chest**

Pigeons breast / Symptoms Diagnostics

Symptoms are seldom

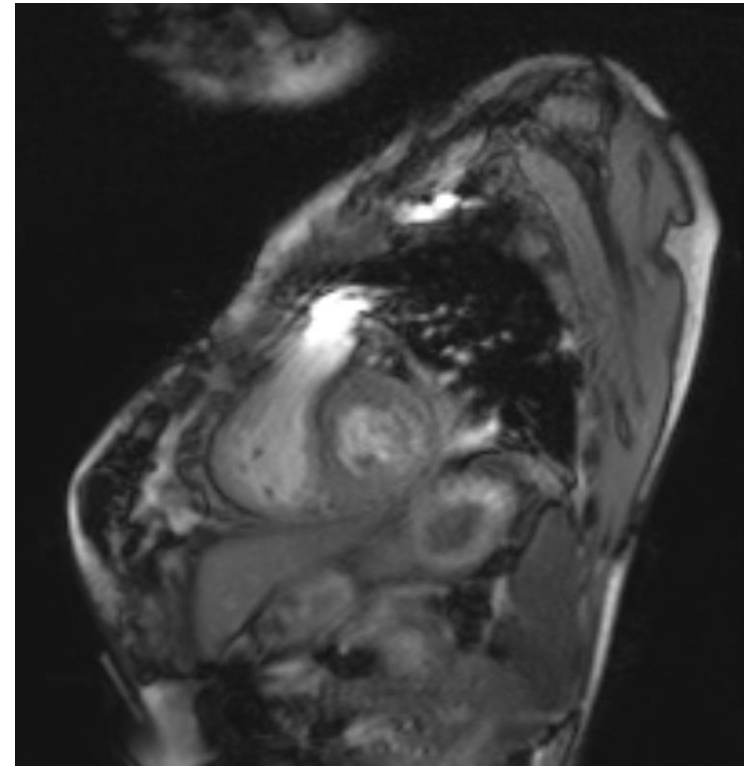
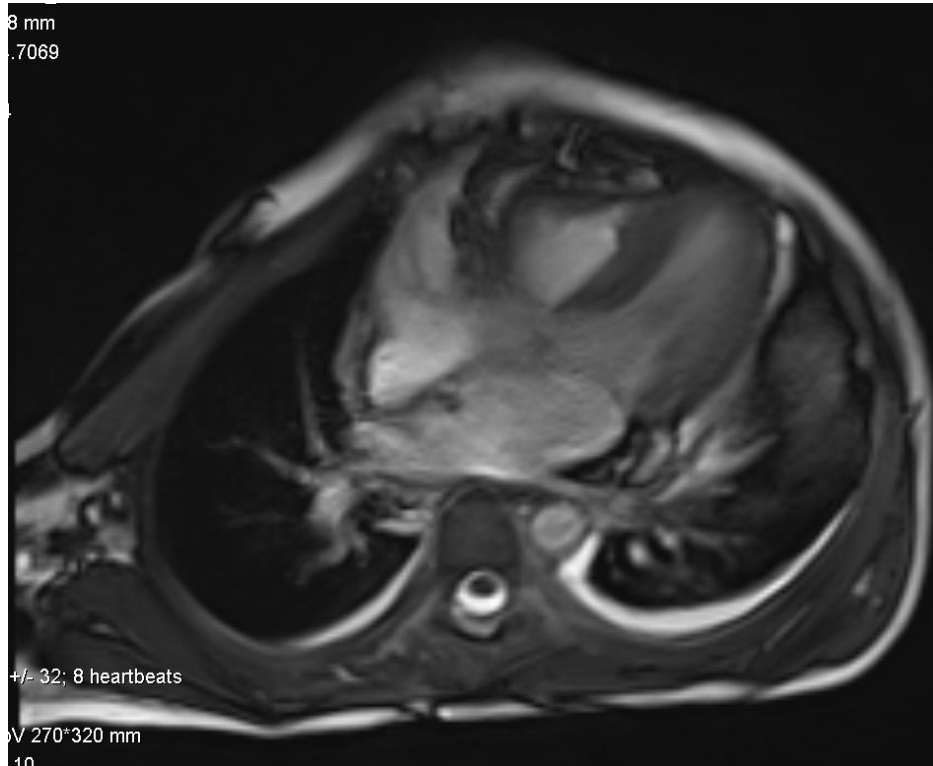
Diagnostics

- Chest X-Ray
- Cardiologic Examination
- Psychological Examination



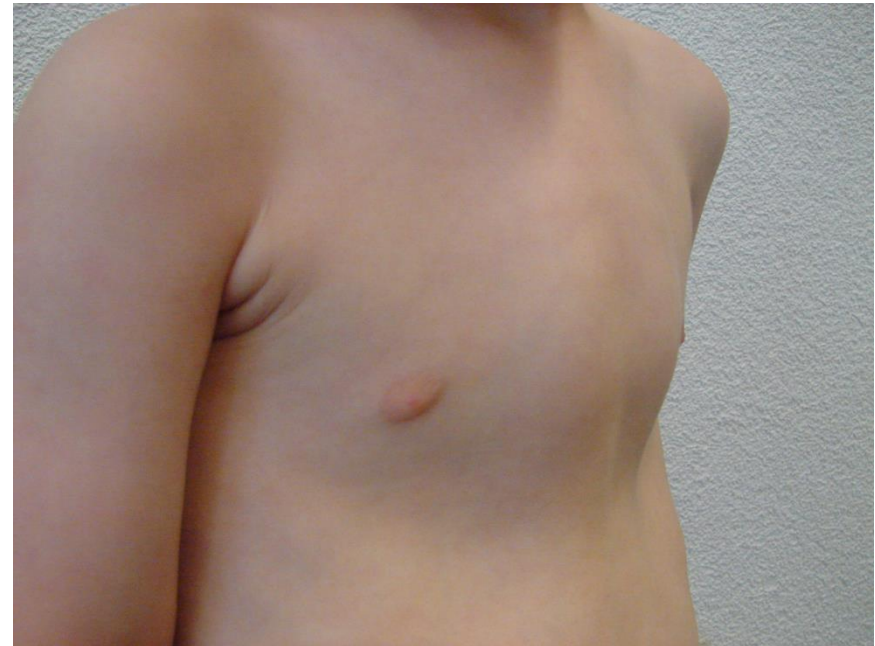Pigeons breast / Diagnostics

MRI

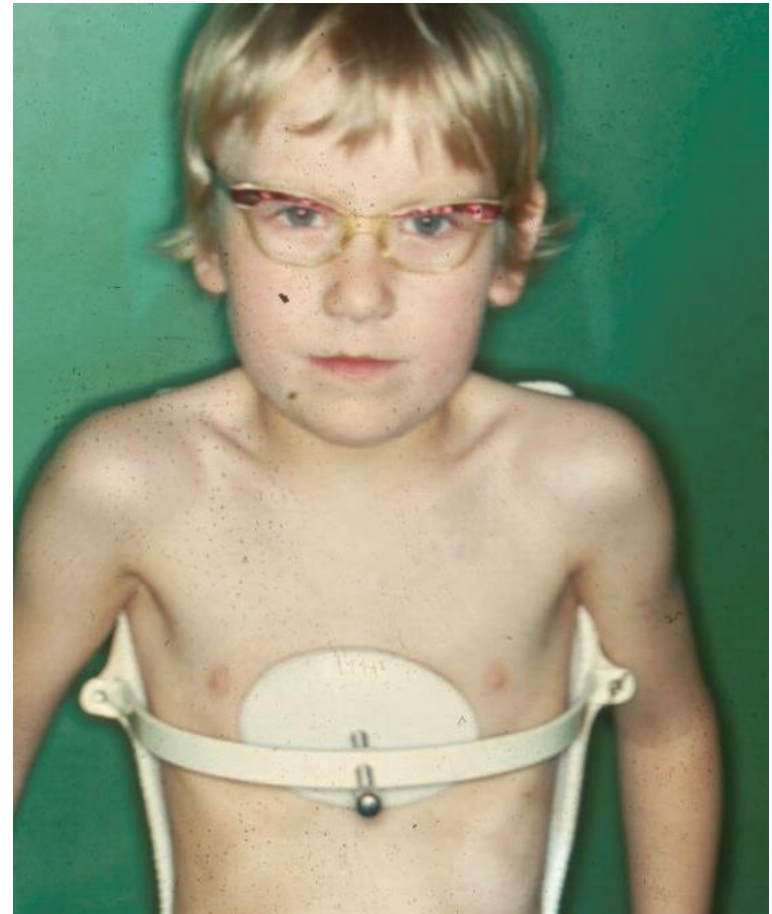
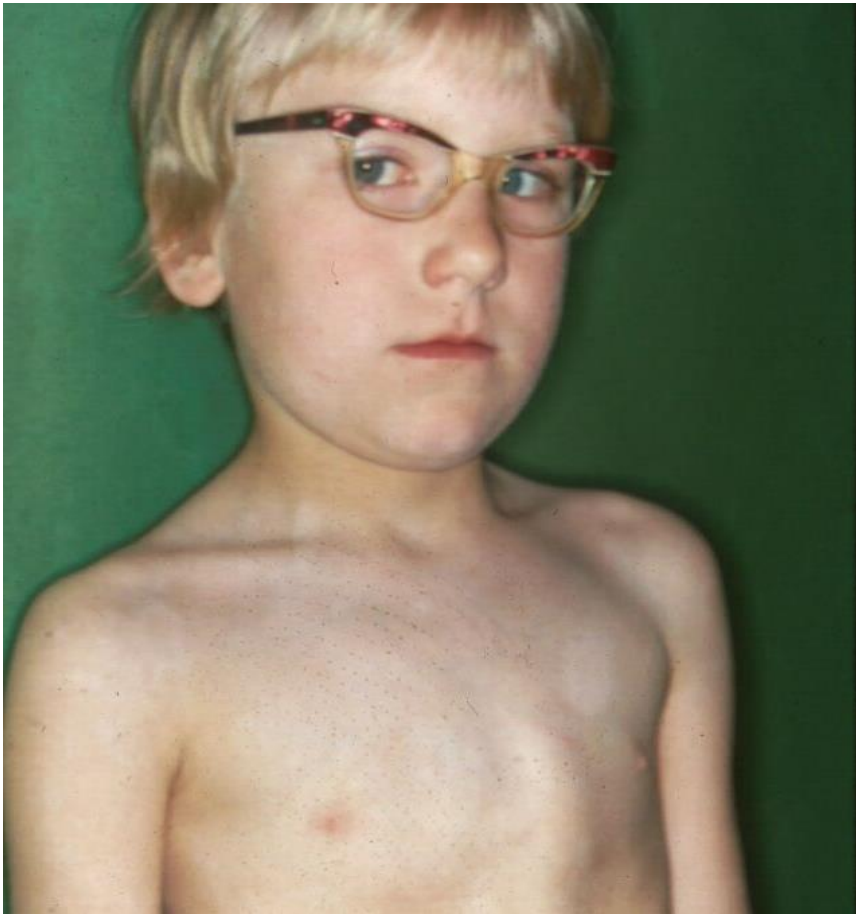

Pigeons breast / Epidemiology

- Appearance 1:1000
- Treatment is indicated for aesthetic and emotional reasons than for cardiorespiratory symptoms
- ca. 5 patients per year

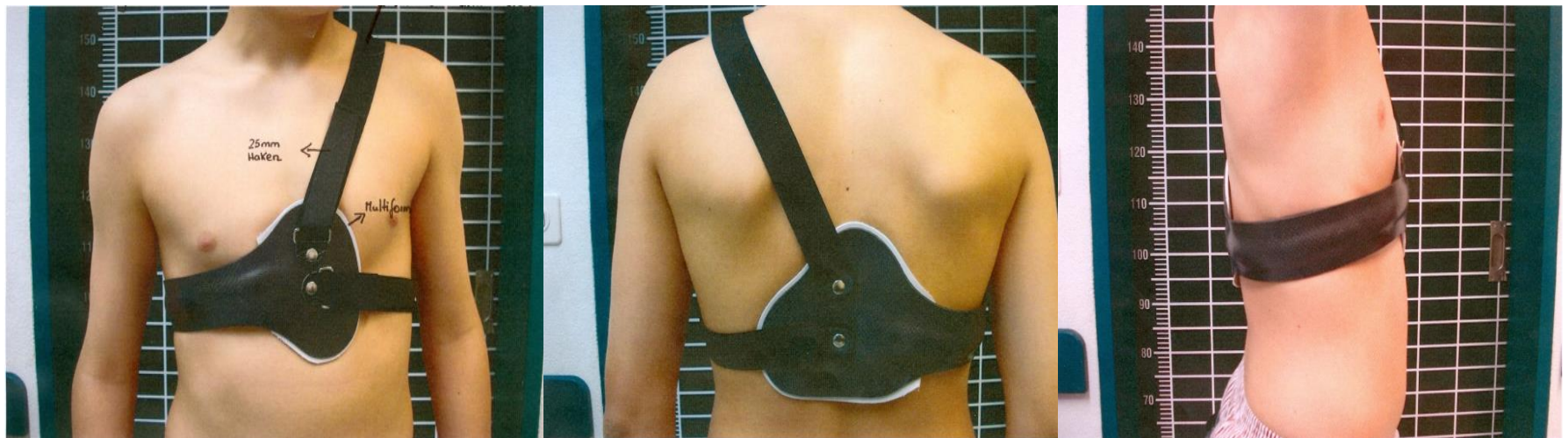


Pigeons breast / Brace therapy

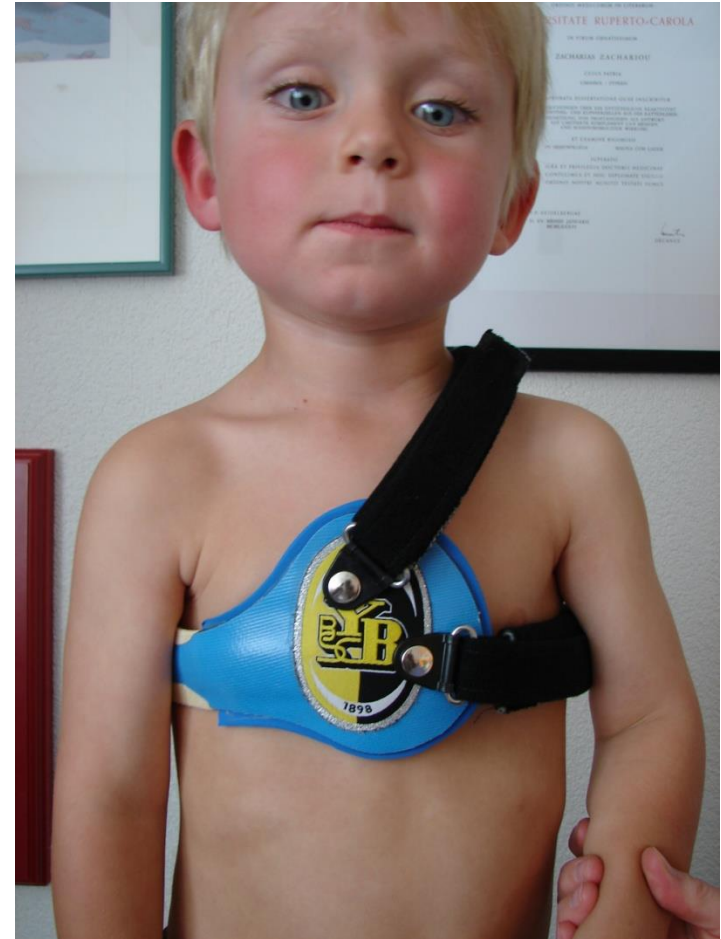
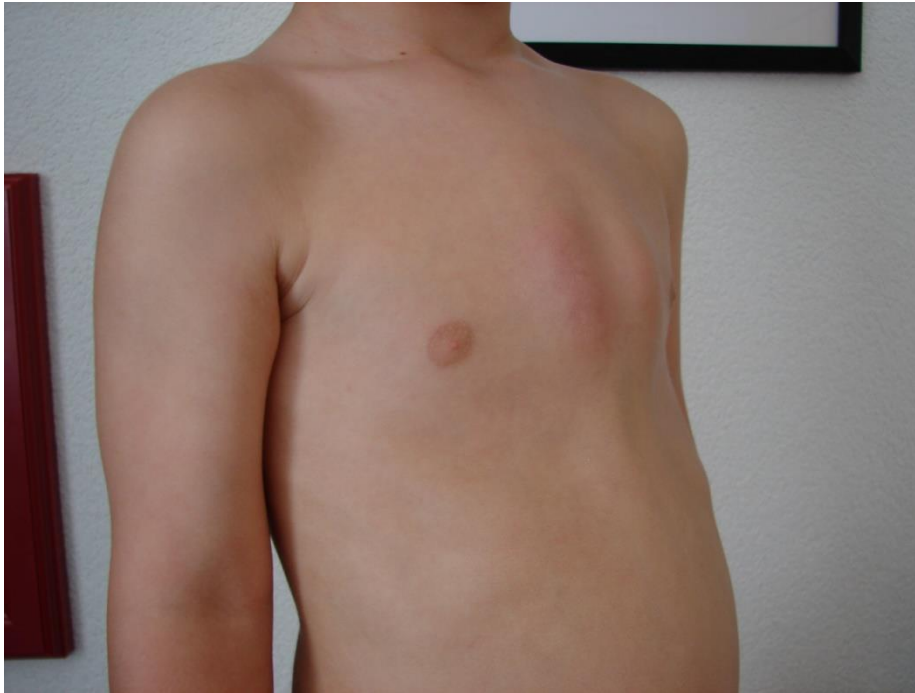
Pigeons breast / Conservative Brace Therapy

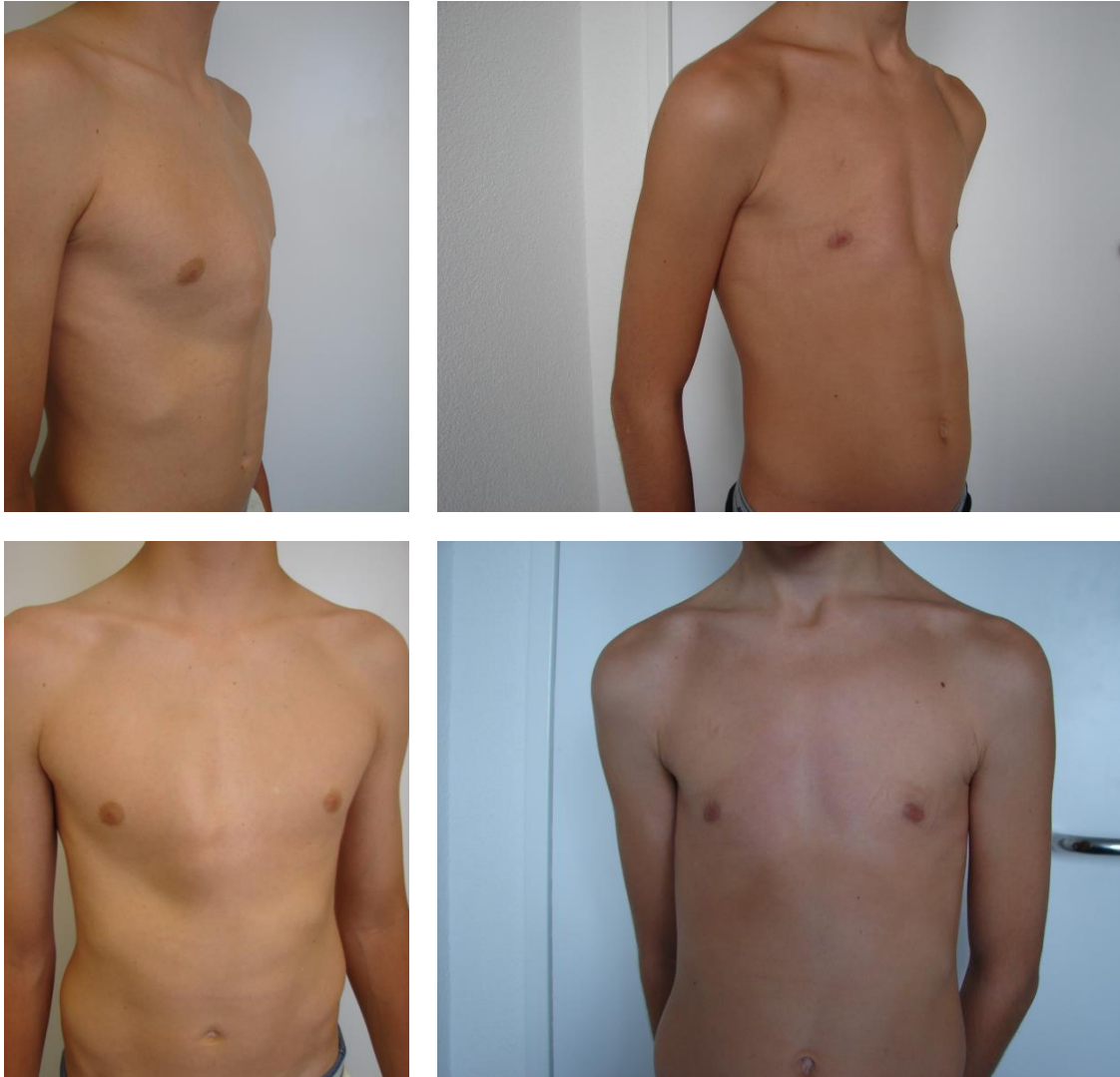
- Individually shaped brace
- Use for 14 days during 24 hours, adaptations
- Use for 6 months 24/24 hours, 6 months during nights



Pigeons breast Results



Pigeons breast Results



Pigeons breast / Patients Questionnaire

2002-2009 (n = 25)

Standardized questionnaire sent out

- Subjective suffering
- Comfort
- Satisfaction with supervision
- Satisfaction with result

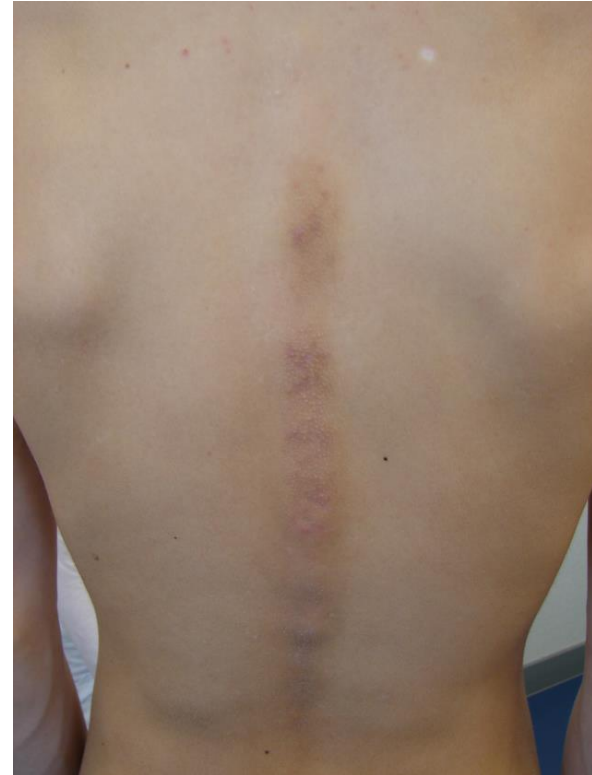Pigeons breast Conservative Therapy

Advantages

- Non-operative
- High success rate

Disadvantages

- Skin irritation, sweating
- Inconvenience during activity
- Visible under the clothes

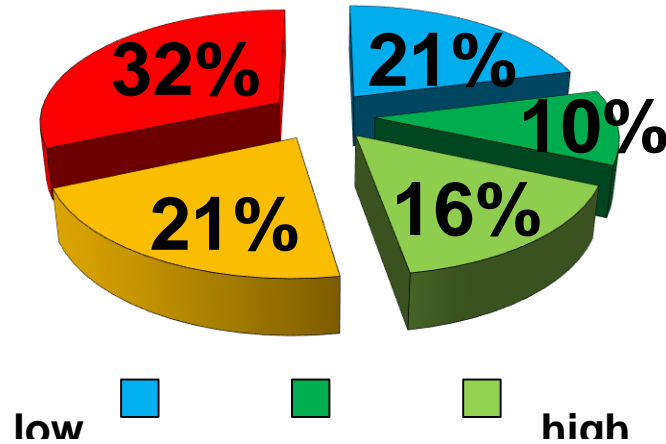


Pigeons breast / Patients Questionnaire

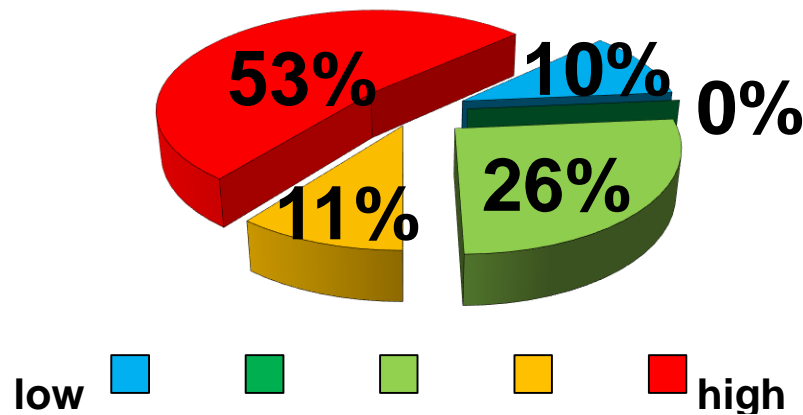
- 23 children/parents answered (92%)
- 3 girls and 20 boys
- Mean age 14.2 years
- Treatment duration: median 12 months
- Corrections of brace: mean 2 times
- Mean follow-up time: 2.5 years
- 85% of the parents would repeat the treatment
- 65% of the children would repeat the treatment

Pigeons breast / Questionnaire Results

Subjective suffering of children before treatment



Satisfaction of children with treatment results



Pigeons breast / Conclusion

- Appropriate individual bracing
- Constant follow-up with controls
- Motivation for a good compliance (child and parents)

Self confident young adults

